

Home (<https://www.indonesianjournalofcancer.or.id/e-journal/index.php/ijoc/index>)

/ Vol 18, No 2 (2024) (<https://www.indonesianjournalofcancer.or.id/e-journal/index.php/ijoc/index>)

Indonesian Journal of Cancer

About Journal

Current Issue

Archives

Announcements

Authors Index

Subject Index

Indonesian Journal of Cancer (p-ISSN 1978-3744 (<http://u.lipi.go.id/1394025747>), the official journal of Dharmais Cancer Hospital - National Cancer Center, is a peer-reviewed, quarterly, and open-access journal. Submissions are reviewed under a broad scope of topics relevant to experimental and clinical cancer research. The journal publishes original research articles, case reports, and review articles under the following focus and scope: cancer management, cancer prevention, cancer etiology, epidemiology, molecular biology, cancer diagnosis and therapy, tumor pathology, surgical oncology, medical oncology, radiation oncology, interventional radiology, as well as early detection.

Accreditation: National Journal Accreditation (ARJUNA) Managed by Ministry of Education, Culture, Research and Technology, the Republic of Indonesia with Second Grade (**SINTA 2**) (<https://sinta3.kemdikbud.go.id/journals/profile/2478>)(No. 200/M/KPT/2020).

Address of the journal's OAI:

<https://www.indonesianjournalofcancer.or.id/e-journal/index.php/ijoc/oai> (/e-journal/index.php/ijoc/oai?verb=Identify)

Indonesian Journal of Cancer Indexed By :



(<https://sinta.kemdikbud.go.id/journals/detail?id=2478>)



(<https://search.crossref.org/?q=indonesian%20journal%20of%20cancer>)



(<https://www.scilit.net/journal/4179514>)



(https://www.worldcat.org/title/indonesian-journal-of-cancer/oclc/652156312&referer=brief_results)

(<https://garuda.kemdikbud.go.id/journal/view/8836>)



(<https://garuda.kemdikbud.go.id/journal/view/8836>)



(<https://scholar.google.co.id/citations?user=MDiYTIUAAAAJ&hl=id&authuser=1>)



(<http://onesearch.id/Record/IOS1.DPMJL-0611000003763#holdings>)



(<https://www.neliti.com/id/journals/indonesian-journal-of-cancer>)



(<https://academic.microsoft.com/journal/2764803462>)

Home (<https://www.indonesianjournalofcancer.or.id/e-journal/index.php/ijoc/index>)

/ About the Journal (<https://www.indonesianjournalofcancer.or.id/e-journal/index.php/ijoc/about>)

/ Editorial Team (<https://www.indonesianjournalofcancer.or.id/e-journal/index.php/ijoc/about/editorialTeam>)

Editorial Team

Editor-in-Chief

- Bayu Brahma, MD, Department of Surgical Oncology Dharmais Cancer Hospital Jakarta, Indonesia

Editorial Board

- Prof. Noorwati Sutandyo, MD, Ph.D, Department of Medical Hematology Oncology Dharmais Cancer Hospital Jakarta, Indonesia
- Samuel J. Haryono, MD, Ph.D, Department of Surgical Oncology Dharmais Cancer Hospital Jakarta, Indonesia
- Prof. Agus Rizal Hamid, MD, Ph.D, Department of Urology, Faculty of Medicine Universitas Indonesia/Cipto Mangunkusumo Hospital, Indonesia
- Prof. Achmad Fauzi Kamal, MD, Ph.D, Department of Orthopaedy & Traumatology Faculty of Medicine Universitas Indonesia - Cipto Mangunkusumo Hospital Jakarta, Indonesia
- Esthika Dewiasty, MD, MSc, Department of Internal Medicine, Clinical Epidemiology Unit, Faculty of Medicine Universitas Indonesia Cipto Mangunkusumo Hospital, Indonesia
- Ramadhan, MD, Ph.D, Department of Surgical Oncology Dharmais Cancer Hospital Jakarta, Indonesia
- Denni Joko Purwanto, MD, Ph.D, Department of Surgical Oncology Dharmais Cancer Hospital Jakarta, Indonesia
- Agus Susanto Kosasih, MD, Ph.D, Department of Clinical Pathology Dharmais Cancer Hospital Jakarta, Indonesia
- Ajoedi, MD, Ph.D, Department of Digestive Surgery Dharmais Cancer Hospital Jakarta, Indonesia
- Rini Andriani, MD, Ph.D, Department of Neurology Dharmais Cancer Hospital Jakarta, Indonesia
- Arif Riswahyudi Hanafi, MD, Ph.D, Department of Pulmonology & Respiratory Medicine Dharmais Cancer Hospital Jakarta, Indonesia
- Widyorini Lestari Hanafi, MD, Department of Gynecologic Oncology Dharmais Cancer Hospital Jakarta, Indonesia
- Nikrial Dewin, MD, Department of Radiotherapy Dharmais Cancer Hospital Jakarta, Indonesia
- Rizky Ifandriani Putri, MD, Department of Anatomical Phatology, Dharmais Cancer Hospital, Jakarta, Indonesia

Managing Editor

- Adhitya Bayu Perdana, National Cancer Center-Dharmais Cancer Hospital, Indonesia
- Leovinna Widjaja, MD, National Cancer Center-Dharmais Cancer Hospital, Indonesia

Assistant Editor

- Ariananda Hariadi, MRCCC Siloam Hospital Semanggi Jakarta, Indonesia
- Jauhari Oka Reuwpassa, Faculty of Public Health, Universitas Indonesia, Indonesia

Editorial Office

- Natarini Setianingsih, National Cancer Center - Dharmais Cancer Hospital, Indonesia

[Aim and Scope \(/e-journal/index.php/ijoc/about/editorialPolicies#focusAndScope\)](/e-journal/index.php/ijoc/about/editorialPolicies#focusAndScope)

[Submit an Article \(/e-journal/index.php/ijoc/about/submissions#onlineSubmissions\)](/e-journal/index.php/ijoc/about/submissions#onlineSubmissions)

[Author Guidelines \(/e-journal/index.php/ijoc/about/submissions\)](/e-journal/index.php/ijoc/about/submissions)

[Reviewer Acknowledgement \(/e-journal/index.php/ijoc/about/displayMembership/1\)](/e-journal/index.php/ijoc/about/displayMembership/1)

[Publication Ethics \(/e-journal/index.php/ijoc/pages/view/Publication-Ethics\)](/e-journal/index.php/ijoc/pages/view/Publication-Ethics)

[Research Article Template \(/e-journal/index.php/ijoc/pages/view/Research%20Article%20Template\)](/e-journal/index.php/ijoc/pages/view/Research%20Article%20Template)

[Case Report Template \(/e-journal/index.php/ijoc/pages/view/Case%20Report%20Article%20Template\)](/e-journal/index.php/ijoc/pages/view/Case%20Report%20Article%20Template)

[Review Article Template \(/e-journal/index.php/ijoc/pages/view/Review%20Article%20Template\)](/e-journal/index.php/ijoc/pages/view/Review%20Article%20Template)

[Article Processing Charge \(/e-journal/index.php/ijoc/about/submissions#authorFees\)](/e-journal/index.php/ijoc/about/submissions#authorFees)

[Publication Frequency \(/e-journal/index.php/ijoc/pages/view/Publication-Frequency\)](/e-journal/index.php/ijoc/pages/view/Publication-Frequency)

JOURNAL CONTENT

Search

Search Scope

All ▼

Search

Browse

- ▶ [By Issue \(https://www.indonesianjournalofcancer.or.id/e-journal/index.php/ijoc/issue/archive\)](https://www.indonesianjournalofcancer.or.id/e-journal/index.php/ijoc/issue/archive)
- ▶ [By Author \(https://www.indonesianjournalofcancer.or.id/e-journal/index.php/ijoc/search/authors\)](https://www.indonesianjournalofcancer.or.id/e-journal/index.php/ijoc/search/authors)
- ▶ [By Title \(https://www.indonesianjournalofcancer.or.id/e-journal/index.php/ijoc/search/titles\)](https://www.indonesianjournalofcancer.or.id/e-journal/index.php/ijoc/search/titles)

VISITOR COUNTER

00786844 (<https://www.statcounter.com/>)

[View My Stats \(http://statcounter.com/p10637180/?guest=1\)](http://statcounter.com/p10637180/?guest=1)

JOURNAL TOOLS




MENDELEY

(<https://www.mendeley.com>)



iThenticate
for Authors & Researchers

(<http://www.ithenticate.com>)



grammarly

(<https://www.grammarly.com>)

Home (<https://www.indonesianjournalofcancer.or.id/e-journal/index.php/ijoc/index>)
/ Archives (<https://www.indonesianjournalofcancer.or.id/e-journal/index.php/ijoc/issue/archive>)
/ Vol 18, No 1 (2024) (<https://www.indonesianjournalofcancer.or.id/e-journal/index.php/ijoc/issue/view/102>)

Vol 18, No 1 (2024)

March

DOI: <https://doi.org/10.33371/ijoc.v18i1> (<https://doi.org/10.33371/ijoc.v18i1>)

Research Article

Differentiation of Serous and Non-serous Epithelial Ovarian Cancer by Radiological Imaging
(<https://www.indonesianjournalofcancer.or.id/e-journal/index.php/ijoc/article/view/1007>)

Devina Yudistiarta, Wigati Dhamiyati, Lina Choridah

 : [10.33371/ijoc.v18i1.1007](https://doi.org/10.33371/ijoc.v18i1.1007) (<http://dx.doi.org/10.33371/ijoc.v18i1.1007>)

 PDF (<https://www.indonesianjournalofcancer.or.id/e-journal/index.php/ijoc/article/view/1007/525>)


|  1-7

The Impact of COVID-19 Pandemic on Ocular Oncology Services at Cipto Mangunkusumo Hospital, Indonesia
(<https://www.indonesianjournalofcancer.or.id/e-journal/index.php/ijoc/article/view/1011>)

Neni Anggraini, Hanifah Rahmani Nursanti, Mutmainah Mahyuddin

 : [10.33371/ijoc.v18i1.1011](https://doi.org/10.33371/ijoc.v18i1.1011) (<http://dx.doi.org/10.33371/ijoc.v18i1.1011>)

 PDF (<https://www.indonesianjournalofcancer.or.id/e-journal/index.php/ijoc/article/view/1011/524>)


|  8-15

Profile of Thyroid Cancer at Dr. Kariadi General Hospital Semarang in 2020 (<https://www.indonesianjournalofcancer.or.id/e-journal/index.php/ijoc/article/view/1017>)

Alif Muhammad Sudarmanto, Yan Wisnu Prajoko, Hermawan Istiadi, Eka Yudhanto

 : [10.33371/ijoc.v18i1.1017](https://doi.org/10.33371/ijoc.v18i1.1017) (<http://dx.doi.org/10.33371/ijoc.v18i1.1017>)

 PDF (<https://www.indonesianjournalofcancer.or.id/e-journal/index.php/ijoc/article/view/1017/526>)


|  16-20

Profile of Rectal Cancer Patients Undergoing Radiation Therapy in Dr. Hasan Sadikin General Hospital From 2016 Until 2021
(<https://www.indonesianjournalofcancer.or.id/e-journal/index.php/ijoc/article/view/1020>)

Nathanael Kurniadi, Marhendra Satria Utama, Andriana Purnama

 : [10.33371/ijoc.v18i1.1020](https://doi.org/10.33371/ijoc.v18i1.1020) (<http://dx.doi.org/10.33371/ijoc.v18i1.1020>)

 PDF (<https://www.indonesianjournalofcancer.or.id/e-journal/index.php/ijoc/article/view/1020/527>)


|  21-26

Analysis of Presentation Delay in Patients with Advanced Breast Cancer Visiting Dharmais National Cancer Hospital
(<https://www.indonesianjournalofcancer.or.id/e-journal/index.php/ijoc/article/view/1025>)

Iskandar Iskandar, Retna Siwi Padmawati, Susanna Hilda Hutajulu, Meidina Fajrin

 : [10.33371/ijoc.v18i1.1025](https://doi.org/10.33371/ijoc.v18i1.1025) (<http://dx.doi.org/10.33371/ijoc.v18i1.1025>)

 PDF (<https://www.indonesianjournalofcancer.or.id/e-journal/index.php/ijoc/article/view/1025/528>)

|  27-31

Performance of Pre-Operative IOTA Three-Step Algorithm in Detecting Ovarian Carcinoma in a Referral Center in Indonesia (<https://www.indonesianjournalofcancer.or.id/e-journal/index.php/ijoc/article/view/1044>)

Andi Kurniadi, Wiryawan Permadi, Aria Yusti Kusuma, Jessica Kireina, Mia Yasmina Andarini, Gatot Nyarumenteng Adhipurnawan Winarno, Ali Budi Harsono

doi: 10.33371/ijoc.v18i1.1044 (<http://dx.doi.org/10.33371/ijoc.v18i1.1044>)

[PDF \(https://www.indonesianjournalofcancer.or.id/e-journal/index.php/ijoc/article/view/1044/529\)](https://www.indonesianjournalofcancer.or.id/e-journal/index.php/ijoc/article/view/1044/529)

| 32-35

A Qualitative Study To Explore the Impact of Having Children with Cancer and Parental Adjustment (<https://www.indonesianjournalofcancer.or.id/e-journal/index.php/ijoc/article/view/1048>)

Ikeu Nurhidayah, Nani Nurhaeni, Allenidekania Allenidekania, Dewi Gayatri, Sri Hendrawati

doi: 10.33371/ijoc.v18i1.1048 (<http://dx.doi.org/10.33371/ijoc.v18i1.1048>)

[PDF \(https://www.indonesianjournalofcancer.or.id/e-journal/index.php/ijoc/article/view/1048/530\)](https://www.indonesianjournalofcancer.or.id/e-journal/index.php/ijoc/article/view/1048/530)

| 36-46

Neutrophil to Hemoglobin Lymphocyte Ratio (NHLR) as a Novel Biomarker is Superior to Neutrophil Lymphocyte Ratio (NLR) and Platelet Lymphocyte Ratio (PLR) as Predictors of Advanced Colorectal Cancer (<https://www.indonesianjournalofcancer.or.id/e-journal/index.php/ijoc/article/view/1099>)

Heri Purnomo, Yuda Handaya, Nurcahya Setyawan

doi: 10.33371/ijoc.v18i1.1099 (<http://dx.doi.org/10.33371/ijoc.v18i1.1099>)

[PDF \(https://www.indonesianjournalofcancer.or.id/e-journal/index.php/ijoc/article/view/1099/531\)](https://www.indonesianjournalofcancer.or.id/e-journal/index.php/ijoc/article/view/1099/531)

| 47-52

Case Report

Total Knee Replacement of Synovial Haemangioma of The Knee Joint in a 44-Year-Old Male: A Case Report (<https://www.indonesianjournalofcancer.or.id/e-journal/index.php/ijoc/article/view/911>)

Mujaddid Idulhaq, Rhyan Darma Saputra, Brian Wasita, Lely Sabariyah, Fajar Baskoro Gardjito, Fajar Nursulistyo

doi: 10.33371/ijoc.v18i1.911 (<http://dx.doi.org/10.33371/ijoc.v18i1.911>)

[PDF \(https://www.indonesianjournalofcancer.or.id/e-journal/index.php/ijoc/article/view/911/532\)](https://www.indonesianjournalofcancer.or.id/e-journal/index.php/ijoc/article/view/911/532)

| 53-56

Diffused Pulmonary Uptake of Tc-99m Methylene Diphosphonate Bone Scan in Patient with Prostate Cancer without Blood Test and Correlative/Cross-Sectional Imaging Abnormalities: A Case Report (<https://www.indonesianjournalofcancer.or.id/e-journal/index.php/ijoc/article/view/1063>)

Junan Imaniar, Minseok Suh, Ayu Rosemeilia Dewi, Yustia Tuti

doi: 10.33371/ijoc.v18i1.1063 (<http://dx.doi.org/10.33371/ijoc.v18i1.1063>)

[PDF \(https://www.indonesianjournalofcancer.or.id/e-journal/index.php/ijoc/article/view/1063/533\)](https://www.indonesianjournalofcancer.or.id/e-journal/index.php/ijoc/article/view/1063/533)

| 57-60

Acute Myeloid Leukemia in a Three-Year-Old Girl Mimicking Chronic Myeloid Leukemia in Blast Crisis, Challenge in Diagnosis and Treatment in Limited-Resourced Health Care Facility: A Case Report (<https://www.indonesianjournalofcancer.or.id/e-journal/index.php/ijoc/article/view/1073>)

Ni Luh Putu Diaswari Predani, Andre Gunawan, Putu Pradnyanita Mustika, I Gusti Ayu Wiradari Tedja

doi: 10.33371/ijoc.v18i1.1073 (<http://dx.doi.org/10.33371/ijoc.v18i1.1073>)

[PDF \(https://www.indonesianjournalofcancer.or.id/e-journal/index.php/ijoc/article/view/1073/534\)](https://www.indonesianjournalofcancer.or.id/e-journal/index.php/ijoc/article/view/1073/534)

| 61-67

Early Recurrence Adenoid Cystic Carcinoma of Paranasal Sinus, A Case Report (<https://www.indonesianjournalofcancer.or.id/e-journal/index.php/ijoc/article/view/1081>)

Nikrial Dewin Marzaini, MD, Handoko Nugroho Yossarsongko, Farilaila Rayhani, Dewi Syafriyetti Soeis

doi: 10.33371/ijoc.v18i1.1081 (<http://dx.doi.org/10.33371/ijoc.v18i1.1081>)

[PDF \(https://www.indonesianjournalofcancer.or.id/e-journal/index.php/ijoc/article/view/1081/535\)](https://www.indonesianjournalofcancer.or.id/e-journal/index.php/ijoc/article/view/1081/535)


| 68-71

Cerebral Tuberculomas Mimicking A Brain Tumor: Report of Two Cases (<https://www.indonesianjournalofcancer.or.id/e-journal/index.php/ijoc/article/view/1084>)

Arwinder Singh Gill, Muhammad Firdaus, Yosafat Kurniawan Sugiarto, Farilaila Rayhani, Rini Andriani, Ahmad Faried

 : 10.33371/ijoc.v18i1.1084 (<http://dx.doi.org/10.33371/ijoc.v18i1.1084>)

 PDF (<https://www.indonesianjournalofcancer.or.id/e-journal/index.php/ijoc/article/view/1084/536>)


|  72-76

Presacral Schwannoma Resembling Lymph Node Metastasis in a Patient with Locally Advanced Prostate Cancer (<https://www.indonesianjournalofcancer.or.id/e-journal/index.php/ijoc/article/view/1096>)

Yukihiro Hama, Etsuko Tate

 : 10.33371/ijoc.v18i1.1096 (<http://dx.doi.org/10.33371/ijoc.v18i1.1096>)

 PDF (<https://www.indonesianjournalofcancer.or.id/e-journal/index.php/ijoc/article/view/1096/539>)


|  77-80

A Rare Parathyroid Carcinoma in Young Adult Man: Therapeutic Challenges in Tertiary Hospital with its Limitations (<https://www.indonesianjournalofcancer.or.id/e-journal/index.php/ijoc/article/view/1172>)

Rupita Sari Endangena Sitanggang, Yohana Azhar, Hasrayati Agustina

 : 10.33371/ijoc.v18i1.1172 (<http://dx.doi.org/10.33371/ijoc.v18i1.1172>)

 PDF (<https://www.indonesianjournalofcancer.or.id/e-journal/index.php/ijoc/article/view/1172/540>)

|  81-88


Review Article

Activity of Matrix Metalloproteinase-7 (MMP-7) Related to Heparin-Binding Epidermal Growth Factor (HB-EGF) Activation in Squamous Cell as Diagnostic Biomarker for Early Detection And Treatment of Maxilarian Cancer: Review Article (<https://www.indonesianjournalofcancer.or.id/e-journal/index.php/ijoc/article/view/1028>)

Gregorius William Thongiratama, Gede Arya Diva Dhananjaya, Happy Kusuma Mulya, I Made Winarsa Ruma

 : 10.33371/ijoc.v18i1.1028 (<http://dx.doi.org/10.33371/ijoc.v18i1.1028>)

 PDF (<https://www.indonesianjournalofcancer.or.id/e-journal/index.php/ijoc/article/view/1028/541>)


|  89-98

Tumor Microenvironment in Colorectal Cancer Development: A Review of 3D Study Analysis (<https://www.indonesianjournalofcancer.or.id/e-journal/index.php/ijoc/article/view/1089>)

Rebecca Noerjani Angka, Aru Wisaksono Sudoyo, Nurjati Chairani Siregar, Wifanto Saditya Jeo, Radiana Dhewayani Antarianto

 : 10.33371/ijoc.v18i1.1089 (<http://dx.doi.org/10.33371/ijoc.v18i1.1089>)

 PDF (<https://www.indonesianjournalofcancer.or.id/e-journal/index.php/ijoc/article/view/1089/542>)


|  96-106

The Role of Acupuncture in Cancer Care: From Symptom Alleviation to Tumor Suppression: A Narrative Review (<https://www.indonesianjournalofcancer.or.id/e-journal/index.php/ijoc/article/view/1111>)

Natasha Setiawan, Hasan Mihardja

 : 10.33371/ijoc.v18i1.1111 (<http://dx.doi.org/10.33371/ijoc.v18i1.1111>)

 PDF (<https://www.indonesianjournalofcancer.or.id/e-journal/index.php/ijoc/article/view/1111/543>)

|  107-113

[Aim and Scope \(/e-journal/index.php/ijoc/about/editorialPolicies#focusAndScope\)](/e-journal/index.php/ijoc/about/editorialPolicies#focusAndScope)

[Submit an Article \(/e-journal/index.php/ijoc/about/submissions#onlineSubmissions\)](/e-journal/index.php/ijoc/about/submissions#onlineSubmissions)

[Author Guidelines \(/e-journal/index.php/ijoc/about/submissions\)](/e-journal/index.php/ijoc/about/submissions)

[Reviewer Acknowledgement \(/e-journal/index.php/ijoc/about/displayMembership/1\)](/e-journal/index.php/ijoc/about/displayMembership/1)

Home (<https://www.indonesianjournalofcancer.or.id/e-journal/index.php/ijoc/index>)

/ Vol 18, No 1 (2024) (<https://www.indonesianjournalofcancer.or.id/e-journal/index.php/ijoc/issue/view/102>)

/ Gill (<https://www.indonesianjournalofcancer.or.id/e-journal/index.php/ijoc/article/view/1084/0>)

Cerebral Tuberculomas Mimicking A Brain Tumor: Report of Two Cases

Arwinder Singh Gill, Muhammad Firdaus, Yosafat Kurniawan Sugiarto, Farilaila Rayhani, Rini Andriani, Ahmad Faried

Abstract

Introduction : Cerebral tuberculoma, a seldom encountered and severe manifestation of tuberculosis (TB), arises from the dissemination of *Mycobacterium tuberculosis* through the bloodstream. Its symptoms and radiological characteristics lack specificity, often resulting in diagnostic errors. Management predominantly involves medical intervention, with the treatment duration for cerebral tuberculoma ranging from 6 to 36 months. In specific instances, surgical intervention may be advised.

Case presentation: We reported two cases of cerebral tuberculoma occurring in patients who presented with seizures, with space-occupying lesions evident on magnetic resonance imaging of the brain. There were no symptoms of concurrent extra cranial TB. Surgery was performed on both of the cases and anti-TB treatment began as soon as the diagnosis was made with corticosteroid as adjuvant treatment.

Conclusion : A combination of clinical, radiological, and histopathological examination is needed to confirm the diagnosis and determine the appropriate therapy. If ICP is increased as a result of the lesion and medical therapy has failed, surgical excision is required.

Keywords

brain tumor, cerebral tuberculoma, tuberculosis, mimicking lesion

Full Text: View (<https://www.indonesianjournalofcancer.or.id/e-journal/index.php/ijoc/article/view/1084/536>) | Download (<https://www.indonesianjournalofcancer.or.id/e-journal/index.php/ijoc/article/download/1084/536>)

DOI: 10.33371/ijoc.v18i1.1084 (<https://doi.org/10.33371/ijoc.v18i1.1084>)

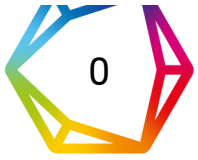Article Metrics

 Abstract View: 347,

 PDF Download: 125

 Total citations

(<https://badge.dimensions.ai/details/doi/10.33371/ijoc.v18i1.1084?>)



0 Recent citations domain=<https://www.indonesianjournalofcancer.or.id>
n/a Field Citation Ratio
n/a Relative Citation Ratio

References

- Perez-Malagon CD, Barrera-Rodriguez R, Lopez-Gonzalez MA, Alva-Lopez LF. Diagnostic and Neurological Overview of Brain Tuberculomas: A Review of Literature. *Cureus*. 2021 Dec 3;13(12):e20133
- WHO Global. Global Tuberculosis Report 2020 [Internet]. World Health Organization. 2020. Available from: <https://www.who.int/publications/i/item/9789240013131>
- Prihutomo S, Slamet, Rustandi K. Pedoman Nasional Pelayanan Kedokteran Tata Laksana Tuberkulosis. Kementerian Kesehatan Republik Indonesia 2015; 2015.
- DeLance AR, Safaee M, Oh MC, et al. Tuberculoma of the central nervous system. *J Clin Neurosci*. 2013;20(10):1333–41.
- Leonard JM. CNS Tuberculosis. In: *Microbiol Spectr*. 2017. p. 17–44.
- Davis AG, Rohlwink UK, Proust A, Figaji AA, Wilkinson RJ. The pathogenesis of tuberculous meningitis. *J Leukoc Biol*. 2019 Feb;105(2):267–280.
- Be N, Kim K, Bishai W, Jain S. Pathogenesis of Central Nervous System Tuberculosis. *Curr Mol Med*. 2009 Mar 1;9(2):94–9.
- Bermudez LE, Sangari FJ. Cellular and molecular mechanisms of internalization of mycobacteria by host cells. *Microbes Infect*. 2001;3(1):37–42.
- Nelson CA, Zunt JR. Tuberculosis of the central nervous system in immunocompromised patients: HIV infection and solid organ transplant recipients. *Clin Infect Dis*. 2011;53(9):915–26.
- Rajeswari R, Sivasubramanian S, Balambal R, et al. A controlled clinical trial of short-course chemotherapy for tuberculoma of the brain. *Tuber Lung Dis*. 1995;76(4):311–7.
- Gregol BM, Berres TO, Barreto T, et al. Brain Tuberculoma as a Differential Diagnosis of Single Intracranial Lesion: Case Report. *Arq Bras Neurocir Brazilian Neurosurg*. 2020;39(02):142–5.
- Moussa AA, Mahmoud ME, Yousef HA. Intracranial tuberculoma and recent advances in magnetic resonance imaging. *Egypt J Neurosurg*. 2018;33:1–5.
- Marais S, Van Toorn R, Chow FC, et al. Management of intracranial tuberculous mass lesions: how long should we treat for? *Wellcome Open Res*. 2019;4.
- Jacobs RF, Sunakorn P, Chotpitayasuno T, et al. Intensive short course chemotherapy for tuberculous meningitis. *Pediatr Infect Dis J*. 1992;11(3):194–7.

Refbacs

■ There are currently no rebfacs.



(<https://creativecommons.org/licenses/by-nc/4.0/>)

This work is licensed under a Creative Commons Attribution-NonCommercial 4.0 International License (<https://creativecommons.org/licenses/by-nc/4.0/>).

[Submit an Article \(/e-journal/index.php/ijoc/about/submissions#onlineSubmissions\)](#)

[Author Guidelines \(/e-journal/index.php/ijoc/about/submissions\)](#)

[Reviewer Acknowledgement \(/e-journal/index.php/ijoc/about/displayMembership/1\)](#)

[Publication Ethics \(/e-journal/index.php/ijoc/pages/view/Publication-Ethics\)](#)

[Research Article Template \(/e-journal/index.php/ijoc/pages/view/Research%20Article%20Template\)](#)

[Case Report Template \(/e-journal/index.php/ijoc/pages/view/Case%20Report%20Article%20Template\)](#)

[Review Article Template \(/e-journal/index.php/ijoc/pages/view/Review%20Article%20Template\)](#)


[Article Processing Charge \(/e-journal/index.php/ijoc/about/submissions#authorFees\)](#)


[Publication Frequency \(/e-journal/index.php/ijoc/pages/view/Publication-Frequency\)](#)

ARTICLE TOOLS


 [Abstract \(https://www.indonesianjournalofcancer.or.id/e-journal/index.php/ijoc/article/view/1084\)](https://www.indonesianjournalofcancer.or.id/e-journal/index.php/ijoc/article/view/1084)

 [Print this article \(https://www.indonesianjournalofcancer.or.id/e-journal/index.php/ijoc/article/download/1084/0\)](https://www.indonesianjournalofcancer.or.id/e-journal/index.php/ijoc/article/download/1084/0)


 [Indexing metadata](#)

 [How to cite item](#)

 [Finding References](#)

 [Review policy \(https://www.indonesianjournalofcancer.or.id/e-journal/index.php/ijoc/about/editorialPolicies#peerReviewProcess\)](https://www.indonesianjournalofcancer.or.id/e-journal/index.php/ijoc/about/editorialPolicies#peerReviewProcess)

 [Email this article \(Login required\)](#)

 [Email the author \(Login required\)](#)

ABOUT THE AUTHORS

Arwinder Singh Gill

1. Department of Neurosurgery, Dharmais Cancer Hospital – National Cancer Center, Jakarta, Indonesia 2. Faculty of Medicine, Tarumanagara University, Jakarta, Indonesia
Indonesia

Muhammad Firdaus

Department of Neurosurgery, Dharmais Cancer Hospital – National Cancer Center, Jakarta, Indonesia
Indonesia

Yosafat Kurniawan Sugiarto

Department of Neurosurgery, Faculty of Medicine, Universitas Padjajaran – Dr. Hasan Sadikin Hospital, Bandung, Indonesia
Indonesia

Farilaila Rayhani

Department of Anatomical Pathology, Dharmais Cancer Hospital – National Cancer Center, Jakarta, Indonesia
Indonesia

Rini Andriani

Department of Neurology, Dharmais Cancer Hospital – National Cancer Center, Jakarta, Indonesia
Indonesia

Ahmad Faried

Department of Neurosurgery, Faculty of Medicine, Universitas Padjajaran – Dr. Hasan Sadikin Hospital, Bandung, Indonesia
Indonesia

JOURNAL CONTENT

Search

Search Scope

Search

Browse

- ▶ By Issue (<https://www.indonesianjournalofcancer.or.id/e-journal/index.php/ijoc/issue/archive>)
- ▶ By Author (<https://www.indonesianjournalofcancer.or.id/e-journal/index.php/ijoc/search/authors>)
- ▶ By Title (<https://www.indonesianjournalofcancer.or.id/e-journal/index.php/ijoc/search/titles>)

VISITOR COUNTER

00786832 (<https://www.statcounter.com/>)

View My Stats (<http://statcounter.com/p10637180/?guest=1>)

JOURNAL TOOLS



(<https://www.mendeley.com>)



(<http://www.ithenticate.com>)



(<https://www.grammarly.com>)

Policies

Focus and Scope (<https://www.indonesianjournalofcancer.or.id/e-journal/index.php/ijoc/about/editorialPolicies#focusAndScope>)

Section Policies (<https://www.indonesianjournalofcancer.or.id/e-journal/index.php/ijoc/about/editorialPolicies#sectionPolicies>)

Peer Review Process (<https://www.indonesianjournalofcancer.or.id/e-journal/index.php/ijoc/about/editorialPolicies#peerReviewProcess>)

Open Access Policy (<https://www.indonesianjournalofcancer.or.id/e-journal/index.php/ijoc/about/editorialPolicies#openAccessPolicy>)

Submissions

Online Submissions (<https://www.indonesianjournalofcancer.or.id/e-journal/index.php/ijoc/about/submissions#onlineSubmissions>)

[Author Guidelines \(https://www.indonesianjournalofcancer.or.id/e-journal/index.php/ijoc/about/submissions#authorGuidelines\)](https://www.indonesianjournalofcancer.or.id/e-journal/index.php/ijoc/about/submissions#authorGuidelines)

[Copyright Notice \(https://www.indonesianjournalofcancer.or.id/e-journal/index.php/ijoc/about/submissions#copyrightNotice\)](https://www.indonesianjournalofcancer.or.id/e-journal/index.php/ijoc/about/submissions#copyrightNotice)

[Privacy Statement \(https://www.indonesianjournalofcancer.or.id/e-journal/index.php/ijoc/about/submissions#privacyStatement\)](https://www.indonesianjournalofcancer.or.id/e-journal/index.php/ijoc/about/submissions#privacyStatement)

[Author Fees \(https://www.indonesianjournalofcancer.or.id/e-journal/index.php/ijoc/about/submissions#authorFees\)](https://www.indonesianjournalofcancer.or.id/e-journal/index.php/ijoc/about/submissions#authorFees)

Other

[Journal Sponsorship \(https://www.indonesianjournalofcancer.or.id/e-journal/index.php/ijoc/about/journalSponsorship\)](https://www.indonesianjournalofcancer.or.id/e-journal/index.php/ijoc/about/journalSponsorship)

[Site Map \(https://www.indonesianjournalofcancer.or.id/e-journal/index.php/ijoc/about/siteMap\)](https://www.indonesianjournalofcancer.or.id/e-journal/index.php/ijoc/about/siteMap)

[About this Publishing System \(https://www.indonesianjournalofcancer.or.id/e-journal/index.php/ijoc/about/aboutThisPublishingSystem\)](https://www.indonesianjournalofcancer.or.id/e-journal/index.php/ijoc/about/aboutThisPublishingSystem)

Share

Post

 Share 0

ISSN: 2355-6811

Cerebral Tuberculomas Mimicking A Brain Tumor: Report of Two Cases

Arwinder Singh Gill^{1,2}, **Muhammad Firdaus**¹, **Yosafat Kurniawan Sugiarto**³,
Farilaila Rayhani⁴, **Rini Andriani**⁵, **Ahmad Faried**^{3*}

¹ Department of Neurosurgery, Dharmais Cancer Hospital – National Cancer Center, Jakarta, Indonesia

² Faculty of Medicine, Tarumanagara University, Jakarta, Indonesia

³ Department of Neurosurgery, Faculty of Medicine, Universitas Padjadjaran – Dr. Hasan Sadikin Hospital, Bandung, Indonesia

⁴ Department of Anatomical Pathology, Dharmais Cancer Hospital – National Cancer Center, Jakarta, Indonesia;

⁵ Department of Neurology, Dharmais Cancer Hospital – National Cancer Center, Jakarta, Indonesia

ARTICLE INFO

Received : 13 June 2023

Reviewed : 18 July 2023

Accepted : 25 September 2023

Keywords:

brain tumor, cerebral tuberculoma,
tuberculosis, mimicking lesion

***Corresponding author:**

Ahmad Faried

Department of Neurosurgery, Faculty
of Medicine, Universitas Padjadjaran,
Jl. Pasteur No. 38, Bandung 40161,
West Java, Indonesia.
ahmad.faried@unpad.ac.id

ABSTRACT

Introduction: Cerebral tuberculoma, a seldom encountered and severe manifestation of tuberculosis (TB), arises from the dissemination of *Mycobacterium tuberculosis* through the bloodstream. Its symptoms and radiological characteristics lack specificity, often resulting in diagnostic errors. Management predominantly involves medical intervention, with the treatment duration for cerebral tuberculoma ranging from 6 to 36 months. In specific instances, surgical intervention may be advised.

Case Presentation: We reported two cases of cerebral tuberculoma occurring in patients who presented with seizures, with space-occupying lesions evident on magnetic resonance imaging of the brain. There were no symptoms of concurrent extra cranial TB. Surgery was performed on both of the cases and anti-TB treatment began as soon as the diagnosis was made with corticosteroid as adjuvant treatment.

Conclusions: A combination of clinical, radiological, and histopathological examination is needed to confirm the diagnosis and determine the appropriate therapy. If ICP is increased as a result of the lesion and medical therapy has failed, surgical excision is required.

INTRODUCTION

Tuberculosis (TB) stands as among the most ancient infectious ailments in human history, attributed to *Mycobacterium tuberculosis*. Its prevalence persists notably in developing nations, impacting a considerable segment of the global populace. TB has the capability to afflict nearly all bodily tissues, encompassing the central nervous system, where it manifests as one of the most severe variants [1].

The 2020 WHO global report revealed that Southeast Asia (43%), Africa (25%), and the Western Pacific (18%) regions harbored the highest incidences of TB cases, while smaller proportions were observed in the Eastern Mediterranean (8.3%), the Americas (3.0%), and Europe (2.3%). The primary impact of the COVID-19 pandemic on TB was a substantial decrease globally in newly diagnosed TB cases reported in 2020 compared to 2019. Indonesia, ranking second only to India, significantly contributed to this global decline from 2019 to 2020.

Despite Indonesia's progress, it remains third in the world for new TB cases. Pulmonary TB is the predominant clinical presentation, accounting for 85.67% of cases, contrasting with extrapulmonary TB at 14.75%. Extrapulmonary TB, particularly affecting the central nervous system (CNS), represents one of the most severe manifestations, afflicting approximately 2-15% of cases, with the highest incidence among individuals with acquired immunodeficiency syndrome (AIDS) [1].

We report two cases of intracranial tuberculoma without any prior history of immunodeficiency. Both cases were managed surgically due to refractory seizures and the mass effect of space-occupying lesions. Anti-TB treatments were administered in both cases with corticosteroid as adjuvant therapy.

CASE PRESENTATION

This case report has been reported in line with the SCARE 2020 criteria [2] and has been approved by our

ethics committee No LB.02.01/X.6.5/69/2022. Patients provided written consent for the publication of this report and the accompanying images.

Case 1

A 59-year-old woman presented to the neurology clinic with focal seizures in her left limb. An episode of clonic-type seizure was reported, without loss of consciousness during the seizure. She disclosed a history of night sweats and weight loss. He denied having ever experienced a fever, a seizure, or a lost consciousness. The patient had no substantial family history, no history of surgery, or daily medication. He had a healthy immune system and had never used immunosuppressive drugs or experienced repeated infections. Neurological examination showed that the patient was fully conscious with peripheral left side cranial nerve VII, cranial nerve XII central, left cranial nerve IX, and X palsy with a slight motoric weakness on left upper limb (motor strength 5/5/4/5). No sensory or autonomy deficit was found. 5 years before this visit, the patient had a history of pulmonary TB and had completed the anti-TB treatment for 6 months. The patient has had a chest X-ray done and there is no sign of TB in the lungs. The HIV test's serology came out negative, and the ESR (erythrocyte sedimentation rate) increased by 62 mm/hour. The patient's brain MRI revealed a well-defined nodular lesion with a hemorrhagic component in the right parietal lobe which enhanced significantly after contrast was delivered. The size of the lesion was 2.3 ×

1.8 cm, with significant perifocal edema and compression of the right lateral ventricle as seen in **Figure 1**.

The patient underwent surgery for excision of the tumor mass and histopathological examination of the specimen acquired. The tumor was brownish white filled with yellowish pus. Tuberculoma was confirmed with granulomatous inflammation, locally visible tubercle formation consisting of epithelioid proliferation, caseous necrosis, and indistinct multinucleated giant cells. Anti-HIV examination, expert genes, and cerebrospinal fluid (CSF) culture showed negative results. Anti-TB medication with isoniazid, rifampicin, pyrazinamide, and ethambutol for 18 months with the addition of streptomycin for 2 initial months was administered with dexamethasone as adjuvant treatment. The patient's symptoms improved after being given dexamethasone adjuvant therapy. There were no adverse events and the frequency of the seizures decreased gradually and eventually stopped. At the end of the treatment, another serial brain MRI was performed for evaluation, and the granulomatous lesion of the right parietal lobe was resolved (**Figure 2**).

Case 2

A 28-year-old man presented to the neurosurgery clinic with weakness in his left limb and a history of uncontrolled focal seizure despite already being on medication for six months. With no medical history, presented with the first seizures in her life and a history of fever, headache, vertigo, nausea, vomiting, and tendencies to fall to the right side when standing.

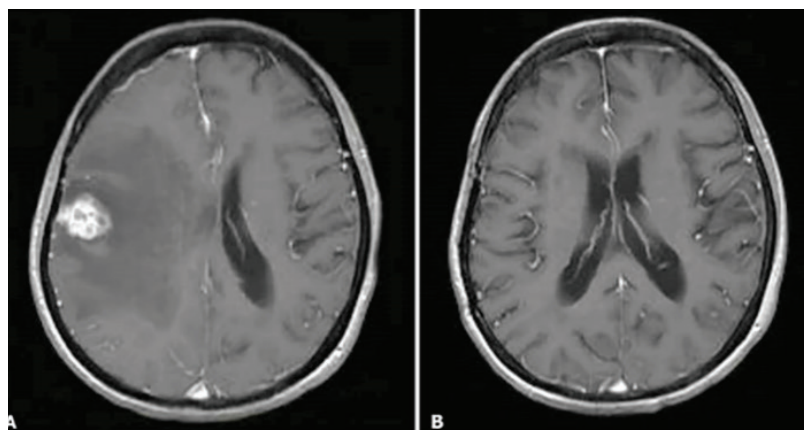


Figure 1. Axial section T1-weighted image with gadolinium contrast on magnetic resonance imaging (MRI). (A) Preoperative; (B) Evaluation after anti-tuberculosis treatment for 18 months was completed.

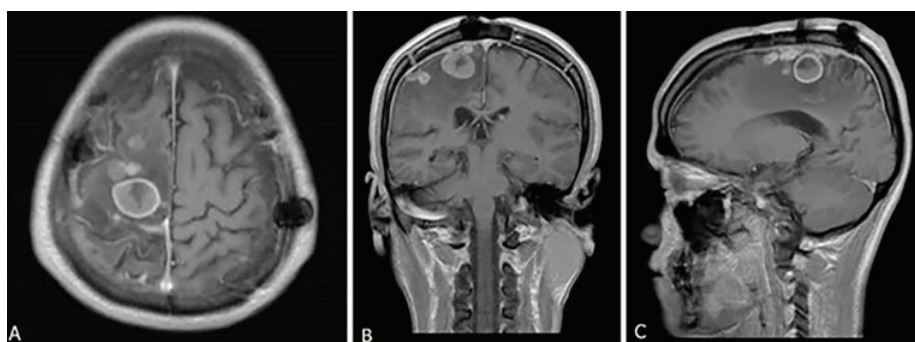


Figure 2. T1-weighted image with gadolinium contrast on MRI before the surgery. (A) Axial Section; (B) Coronal Section; (C) Sagittal Section.

A neurological examination revealed a normal cerebellar function test. Neurological examination showed that the patient was fully conscious with motoric weakness on the left lower limb. No sensory or autonomy deficit was found. Cranial nerve examinations were normal without any deficit. He had previously undergone craniotomy at another hospital 6 months before the visit with histopathology concluding an astrocytoma. The sample was re-assessed at our center and the new result was tuberculoma (**Figure 3**).

The patient never had a previous history of TB. There were continuous focal seizures of the left limb which could not be controlled by antiepileptic drugs. The patient had done a chest x-ray and no new cavitation was found in the lung. The HIV test's serology came out negative, and the erythrocyte sedimentation rate (ESR) increased by 72 mm/hour. Brain MRI on T1-weighted image showed multiple hyperintense lesions predominantly on the right parietal region with perifocal edema. The main lesion was 2.4 x 2.1 cm in size surrounded by smaller lesions of 1.3 x 1.3 cm. A craniotomy was decided as the lesion was not typical for the diagnosis of astrocytoma. The tumor was firm in consistency with clear margins and had necrotic fluid draining from the center of the lesion. The tumor was removed microscopically and the large draining veins were preserved as seen in **Figure 4**.

A cerebrospinal fluid culture was performed and showed microorganisms and gram stain results were negative. HIV testing showed negative results and blood sugar levels were within normal limits which ruled out

immunocompromised risk in the patient. Anti-TB treatment was started as soon as the diagnosis was made with a combination of isoniazid, rifampicin, pyrazinamide, and ethambutol scheduled for 12 months with the addition of streptomycin for the 2 initial months. The patient also had dexamethasone therapy for 1 month. The patient symptoms clinically improved after dexamethasone adjuvant therapy. Throughout the treatment, episodes of seizure still occurred but with longer intervals compared to pre-surgery conditions.

DISCUSSION

Tuberculosis stands as one of the deadliest infectious diseases globally. While it typically affects the respiratory system, CNS TB accounts for approximately 5 to 15% of extrapulmonary cases, posing the highest risks of morbidity and mortality. Central nervous system TB can be categorized into three types: tuberculous meningitis (TBM), spinal arachnoiditis, and cerebral tuberculoma, as exemplified in the cases discussed in our report [3,4,5].

It is widely believed that the bacilli enter the central nervous system through the bloodstream, typically as a result of tuberculosis occurring elsewhere in the body. Rich and McCordock's initial description proposed that tuberculous lesions form in the brain during the bacteremia stage [6]. In theory, tuberculosis has the potential to breach the blood-brain barrier (BBB) either as a free organism outside cells or through monocytes/neutrophils carrying the bacilli [7]. The rupture of one or multiple lesions can lead to the development of CSF

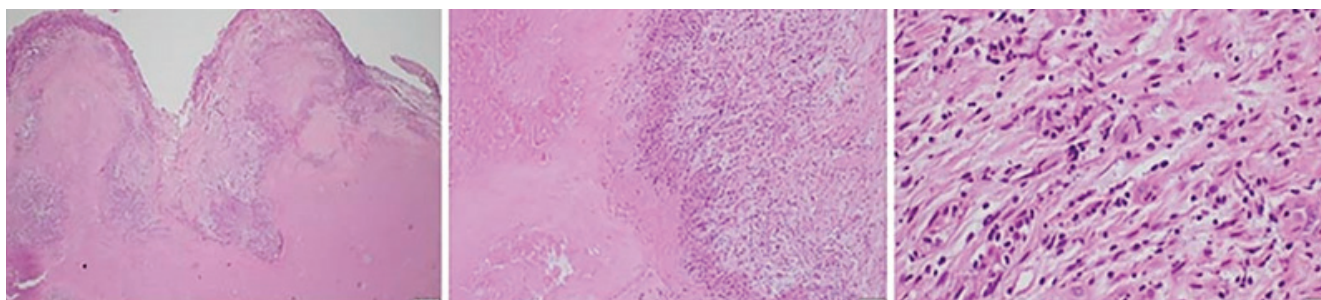


Figure 3. The preparation showed tubercles made up of histiocyte cells, epithelioid cells, lymphocyte cells, and an extensive case of necrosis in the brain tissue. Blood vessels can be found in some of them with original magnification of 4x, 10x, and 40x, respectively.

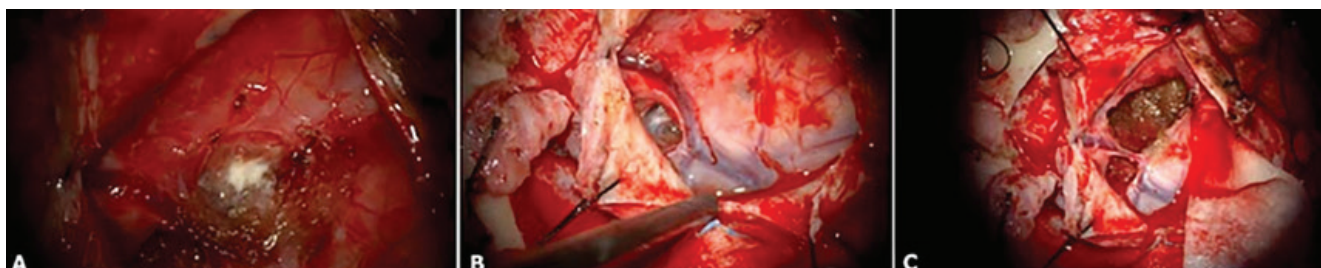


Figure 4. (A) Necrotic fluid at the center of the mass which was yellowish; (B) The large tumor was firm with marked borders that were adherent to the draining vein; (C) Careful lesion dissection showed total removal with preservation of the vein.

TB. These lesions commonly originate in the meninges, subpia, or subependymal surface of the brain. The growth of these lesions is understood to be influenced by the immune system [8]. Individuals diagnosed with human immunodeficiency virus (HIV) infection face a significantly heightened risk of tuberculoma, approximately five times greater than those without HIV. Immunodeficiency, whether due to HIV or organ transplantation and subsequent prolonged use of immunosuppressive drugs, increases the susceptibility to tuberculosis. For recipients of solid organ transplants, the likelihood of developing TB rises by 20–74%. Additionally, approximately 8% of tuberculoma cases are linked to patients having concurrent diabetes [9].

In instances where a tuberculoma grows to a considerable size, it may resemble a brain tumor, exerting pressure on nearby brain tissue and eliciting symptoms indicative of heightened intracranial pressure (ICP), such as headaches, nausea, and vomiting. Seizures are typically the primary symptom upon presentation with tuberculoma, as observed in our case. Distinguishing granulomas from other brain-expansive lesions based solely on neurological symptoms is challenging, as these symptoms are contingent upon the location and size of the lesion. Manifestations of intracranial hypertension and seizures are commonly encountered [1,11]. Cerebral tuberculomas are solid, non-vascular, rounded growths ranging in size from 2 to 10 cm in diameter. They exhibit well-defined boundaries, and the adjacent brain tissue, under pressure, may exhibit swelling and gliosis. Within the mass, there are regions of necrotic caseation where tubercle bacilli may be detected [12]. These are the primary attributes of these lesions, which were also observed during surgical intervention in our cases. They were successfully excised due to their clearly demarcated borders from the adjacent brain structures.

Considering tuberculoma in the list of possible diagnoses is crucial when encountering solitary intracranial mass lesions. However, diagnosing it poses challenges because the neuroimaging presentations can vary and lack specificity. Tuberculomas typically appear on brain scans as isodense or hyperdense lesions, sometimes with calcifications, and exhibit ring enhancement following contrast administration. The presence of calcifications on CT scans along with ring enhancement, termed the “target sign,” is regarded by some authors as potentially specific to tuberculoma. MRI is more adept than CT scans at identifying small tuberculomas and those situated in the brainstem. Typically, tuberculomas display intermediate or low signal intensity on T1-weighted images, accompanied by ring enhancement post-injection of gadolinium. On T2-weighted sequences, they typically exhibit low signal intensity with surrounding edema [1,12]. The lesion locations align with documented literature, as they can manifest as solitary or multiple

growths and tend to occur more frequently in the frontal and parietal lobes [13].

The inflammatory reaction triggered by TB infection is characterized by granulomatous inflammation, featuring epithelioid macrophages and Langhans’ giant cells, alongside lymphocytes, plasma cells, a small number of PMNs, fibroblasts with collagen, and distinctive caseous necrosis at the core. This inflammatory response is driven by a type IV hypersensitivity reaction [7,8,13]. Current treatment for CNS TB typically involves medical therapy, comprising a regimen including isoniazid, ethambutol, pyrazinamide, rifampicin, and steroids. This treatment regimen often leads to a reduction in tuberculoma size and complete resolution within three months, although in some cases, a longer duration of up to three years may be necessary. Patients with elevated intracranial pressure should undergo immediate neurosurgical evaluation. Surgical resection may be necessary for tuberculomas to alleviate mass effect, as prompt removal can significantly enhance overall outcomes, even in cases of drug resistance or paradoxical worsening, affecting up to 25% of treated TB patients. However, this study’s limitation lies in its inability to establish a causal relationship between adjuvant steroids and patient outcomes, as well as the impact of surgery on symptom improvement. Future studies, such as larger case series or multicenter research, are warranted. The choice of surgical approach may vary based on factors including tuberculoma location, surrounding vascular and nerve structures, cortical involvement, and surgeon preference [1,10,13,14].

CONCLUSIONS

Over the past few decades, there has been a remarkable improvement in the prognosis of cerebral tuberculoma, shifting from a prognosis nearly fatal to one where over 80% of patients survive with timely treatments. Considering the possibility of tuberculoma is essential when evaluating CNS masses, even in patients without a history of TB elsewhere, to ensure prompt and appropriate treatment. While imaging studies are supportive, they do not conclusively confirm the diagnosis of brain tuberculoma, and both prognosis and treatment differ from other brain lesions. A histological diagnosis achieved through surgical excision not only confirms the diagnosis but also helps alleviate symptoms of increased intracranial pressure.

DECLARATIONS

Competing of Interest

The authors declare no competing interest in this study.

Acknowledgment

Not applicable

REFERENCES

1. Perez-Malagon CD, Barrera-Rodriguez R, Lopez-Gonzalez MA, Alva-Lopez LF. Diagnostic and Neurological Overview of Brain Tuberculomas: A Review of Literature. *Cureus*. 2021 Dec 3;13(12):e20133
2. WHO Global. Global Tuberculosis Report 2020 [Internet]. World Health Organization. 2020. Available from: <https://www.who.int/publications/i/item/9789240013131>
3. Prihutomo S, Slamet, Rustandi K. Pedoman Nasional Pelayanan Kedokteran Tata Laksana Tuberkulosis. Kementerian Kesehatan Republik Indonesia 2015; 2015.
4. DeLance AR, Safaee M, Oh MC, et al. Tuberculoma of the central nervous system. *J Clin Neurosci*. 2013;20(10):1333–41.
5. Leonard JM. CNS Tuberculosis. In: *Microbiol Spectr*. 2017. p. 17–44.
6. Davis AG, Rohlwink UK, Proust A, Figaji AA, Wilkinson RJ. The pathogenesis of tuberculous meningitis. *J Leukoc Biol*. 2019 Feb;105(2):267–280.
7. Be N, Kim K, Bishai W, Jain S. Pathogenesis of Central Nervous System Tuberculosis. *Curr Mol Med*. 2009 Mar 1;9(2):94–9.
8. Bermudez LE, Sangari FJ. Cellular and molecular mechanisms of internalization of mycobacteria by host cells. *Microbes Infect*. 2001;3(1):37–42.
9. Nelson CA, Zunt JR. Tuberculosis of the central nervous system in immunocompromised patients: HIV infection and solid organ transplant recipients. *Clin Infect Dis*. 2011;53(9):915–26.
10. Rajeswari R, Sivasubramanian S, Balambal R, et al. A controlled clinical trial of short-course chemotherapy for tuberculoma of the brain. *Tuber Lung Dis*. 1995;76(4):311–7.
11. Gregol BM, Berres TO, Barreto T, et al. Brain Tuberculoma as a Differential Diagnosis of Single Intracranial Lesion: Case Report. *Arq Bras Neurocir Brazilian Neurosurg*. 2020;39(02):142–5.
12. Moussa AA, Mahmoud ME, Yousef HA. Intracranial tuberculoma and recent advances in magnetic resonance imaging. *Egypt J Neurosurg*. 2018;33:1–5.
13. Marais S, Van Toorn R, Chow FC, et al. Management of intracranial tuberculous mass lesions: how long should we treat for? *Wellcome Open Res*. 2019;4.
14. Jacobs RF, Sunakorn P, Chotpitayasuno T, et al. Intensive short course chemotherapy for tuberculous meningitis. *Pediatr Infect Dis J*. 1992;11(3):194–7.