

## SURAT TUGAS

Nomor: 49-R/UNTAR/PENELITIAN/VII/2022

Rektor Universitas Tarumanagara, dengan ini menugaskan kepada saudara:

**SUKMAWATI TANSIL TAN, dr., Sp.K.K., Dr.**

Untuk melaksanakan kegiatan penelitian/publikasi ilmiah dengan data sebagai berikut:

Judul : Secretome ? A new ?Cappiler? for Compartement Syndrome  
Nama Media : SAS Journal of Medicine  
Penerbit : SAS PUBLISHER  
Volume/Tahun : 2022 Mar 8(3): 203-208.  
URL Repository : [https://saspublishers.com/media/articles/SASJM\\_83\\_203-208.pdf](https://saspublishers.com/media/articles/SASJM_83_203-208.pdf)

Demikian Surat Tugas ini dibuat, untuk dilaksanakan dengan sebaik-baiknya dan melaporkan hasil penugasan tersebut kepada Rektor Universitas Tarumanagara

06 Juli 2022

Rektor



**Prof. Dr. Ir. AGUSTINUS PURNA IRAWAN**

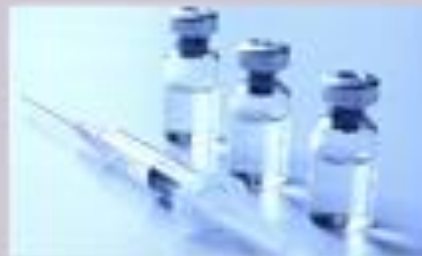Print Security : 260c269ee5965367a1fa518fc92aa8bc

Disclaimer: Surat ini dicetak dari Sistem Layanan Informasi Terpadu Universitas Tarumanagara dan dinyatakan sah secara hukum.

ISSN: 2454-5112

# SAS Journal of Medicine

*Abbreviated key title: SAS J. Med.*



**SAS** Publishers

# SAS Publishers

(An International Publisher for Academic and Scientific Journals)

[Home](#) [For Authors](#) [Journals](#) [Books](#) [Conference](#) [Online Payment](#)

[Copyright](#) [Submit Manuscript](#)

## SAS Journal of Medicine


### Volume-8 - Issue-03

---

Original Research Article

March 10, 2022

#### Liposarcomas: Experience of the Oncology and Radiotherapy Department and the Anatomy-Pathology Department at the Mohammed VI University Hospital in Marrakech: 10-Year Retrospective Study from January 2010 to January 2020

 Basma Mahrouch, Malak Bennani, Ikram Zaytoun, Mouna Darfaoui, Abdelhamid El Omrani, Mouna Khouchani

 SAS J Med | 121-127

 DOI : 10.36347/sasjm.2022.v08i03.001

 ABSTRACT

 PDF


 FULL TEXTS

 E-PUB

Case Report

March 10, 2022

#### Fracture and Migration of Port Catheter: Rare Complication

 Basma Mahrouch, Nassima Kadri, Ikram Zaytoun, Nora Naqos, Mouna Darfaoui, Abdelhamid El Omrani, Mouna Khouchani

 SAS J Med | 128-130

 DOI : 10.36347/sasjm.2022.v08i03.002

 ABSTRACT

 PDF

 FULL TEXTS

 E-PUB

**Case Report****Cardiac Tamponade in Eisenmenger Syndrome: A Diagnosing Complexity: Case Report**

W.Belkho, J.SAFI, L. Rachid, L.Chemaou, Y.Malky, M.El Jamili, S. El Karimi, M. El Hattaoui

SAS J Med | 131-133

DOI : 10.36347/sasjm.2022.v08i03.003

 ABSTRACT

 PDF

 FULL TEXTS

 E-PUB

**Original Research Article****March 11, 2022****Risk Factors and Serum S-100 Protein Level Analysis of Ischaemic Stroke Patients: A Tertiary Care Hospital Study in Bangladesh**

Dr. Shagufta Mehzabeen, Prof. Md. Quddusur Rahman, Dr. Md. Shahidullah Sabuj, Prof. Debatosh Paul, Dr. Sheuly Ferdousi, Prof. Tuhin Sultana, Dr. Md. Saiful Islam, Dr. Md. Abdul Kadir Shahin

SAS J Med | 134-139

DOI : 10.36347/sasjm.2022.v08i03.004

 ABSTRACT

 PDF

 FULL TEXTS

 E-PUB

**Case Report****March 14, 2022****Cardiac Tamponade: A Life Threatening Complication of Adult still's Disease: Case Report and Review of Literature**

W. Belkho, L. Rachid, M.El Jamili, M. El Hattaoui

SAS J Med | 140-142

DOI : 10.36347/sasjm.2022.v08i03.005

 ABSTRACT

 PDF

 FULL TEXTS

 E-PUB

**Original Research Article****March 16, 2022****Adverse Post-Vaccination Events (APEs) in Mali Hospital Following Astrazeneca COVID-19 Vaccine Immunization in Mali**

Dicko Ousmane Attaher, Guédiouma Dembélé, Dramé boubacar Sidiki Ibrahim, Dabo Garan, Samaké Magara, Diallo Djénéba, Awa Tamboura, Ibrahima Farota, Kounandi Diombana, Mohamed Naremba Soumaoro, .....

SAS J Med | 143-149



DOI : 10.36347/sasjm.2022.v08i03.006

 ABSTRACT

 PDF

 FULL TEXTS

 E-PUB

**Case Report****March 16, 2022****Insulinoma: Diagnosis and Management on Two Observations** Bilihi Bouyela N, Ben Lafqih M, Rafi S, El Mghari G, El Ansari N **SAS J Med** | 150-153 **DOI** : 10.36347/sasjm.2022.v08i03.007 **ABSTRACT**  **PDF**  **FULL TEXTS**  **E-PUB****Case Report****March 16, 2022****Dermatomyositis Triggered by Metastatic Subungueal Melanoma: A Case Report and Review of Literature** H.Taoufik, I.Boujguenna, H.Rais, O.Hocar, S. Amal **SAS J Med** | 154-157 **DOI** : 10.36347/sasjm.2022.v08i03.008 **ABSTRACT**  **PDF**  **FULL TEXTS**  **E-PUB****Case Report****March 16, 2022****Coexistence of Large B Cell Non-Hodgkin's Lymphoma and Lymph Node Tuberculosis: A Case Report and Review of Literature** H. Taoufik, I. Boujguenna, H. Rais, O. Hocar, S. Amal **SAS J Med** | 158-160 **DOI** : 10.36347/sasjm.2022.v08i03.009 **ABSTRACT**  **PDF**  **FULL TEXTS**  **E-PUB****Original Research Article****March 16, 2022****Preventing Youth Substance Use Using Creative Problem Solving-Cognitive-Behavioural Skills Enhancement Approach** Felix-Kingsley Obialo **SAS J Med** | 161-166 **DOI** : 10.36347/sasjm.2022.v08i03.010 **ABSTRACT**  **PDF**  **FULL TEXTS**  **E-PUB****Case Report****March 20, 2022**

## Diagnosis of Systemic AL-Type Amyloidosis Revealed by Severe Restrictive Cardiomyopathy: Case Report and Literature Review

Phany Brunelle Issanga Maloumbi, Junior Rocyr Ibara-Onguema, Gildas Ismael Ganse, Mohamed El Jamili, Dounia Benzeroual, Saloua El Karimi, Mustapha El Hattaoui

SAS J Med | 167-170

DOI : 10.36347/sasjm.2022.v08i03.011

 ABSTRACT

 PDF

 FULL TEXTS

 E-PUB

Original Research Article

March 22, 2022

## Our Experience in Approaching and Managing Pregnant Ladies Infected with COVID 19 at Prince Ali Hospital in Jordan

Dr. Tariq Irtaimah, Dr. Amal Dubais, Dr. Kholoud Matar, Dr. Taisser Abbadi, Dr. Anas Masalha

SAS J Med | 171-176

DOI : 10.36347/sasjm.2022.v08i03.012

 ABSTRACT

 PDF

 FULL TEXTS

 E-PUB

Original Research Article

March 22, 2022

## A Five Year Study on Maternal Mortality in The Maternity Ward of Government General Hospital, Siddhartha Medical College, Vijayawada

Dr. G. L. Shobhitha, Dr. G. Priyanka

SAS J Med | 177-182

DOI : 10.36347/sasjm.2022.v08i03.013

 ABSTRACT

 PDF

 FULL TEXTS

 E-PUB

Original Research Article

March 23, 2022

## Incidence of Infective Endocarditis during the Coronavirus Disease 2019: Study of 41 Cases

A. Ait Yahya, M. A. Charik, M. El Jamili, M. El Hattaoui

SAS J Med | 183-187

DOI : 10.36347/sasjm.2022.v08i03.014

 ABSTRACT

 PDF

 FULL TEXTS

 E-PUB

Original Research Article

March 23, 2022

## Acute Coronary Syndrome without ST Elevation: is The Level of Ultrasensitive Troponin T Correlated to the Severity of Coronary Involvement?

 A. Aityahya, M.A. Charik, M. Eljamili, M.Elhattaoui

 **SAS J Med** | 188-192

 **DOI** : 10.36347/sasjm.2022.v08i03.015

 **ABSTRACT**    **PDF**    **FULL TEXTS**   **E-PUB**

**Case Report**


**March 23, 2022**

## Tracheopathia Osteoplastica: Rare Etiology of Hemoptysis

 Hasna Jabri, Asmaa Fahmi, Hajar Arfaoui, Wiam Elkhatabi, Hicham Afif

 **SAS J Med** | 193-196

 **DOI** : 10.36347/sasjm.2022.v08i03.016

 **ABSTRACT**    **PDF**    **FULL TEXTS**   **E-PUB**

**Original Research Article**

**March 25, 2022**

## Evaluation of Lipid Profile and Fasting Blood Glucose Among Pregnant Women at Omdurman Maternity Hospital

 Makawi A. A. Osman, Noon A.Hammed, Elmutaz H.Taha, Mohammed Elshiekh

 **SAS J Med** | 197-202

 **DOI** : 10.36347/sasjm.2022.v08i03.017

 **ABSTRACT**    **PDF**    **FULL TEXTS**   **E-PUB**

**Case Report**

**March 25, 2022**

## Secretome – A new “Cappiler” for Compartement Syndrome

 Sukmawati Tansil Tan, Yohanes Firmansyah, Edwin Destra

 **SAS J Med** | 203-208

 **DOI** : 10.36347/sasjm.2022.v08i03.018

 **ABSTRACT**    **PDF**    **FULL TEXTS**   **E-PUB**

**Original Research Article**

**March 25, 2022**

## Effect of Fasting in Patients Taking Acenocoumarol

 A. Chachi, S. Jourani, A. Benbahia, M. Eljamili, S. Elkarimi, D. Benzarouel, M. Elhattaoui

 **SAS J Med** | 209-211

[DOI : 10.36347/sasjm.2022.v08i03.019](https://doi.org/10.36347/sasjm.2022.v08i03.019)

[ABSTRACT](#) [PDF](#) [FULL TEXTS](#) [E-PUB](#)

### Original Research Article

March 28, 2022

#### Impact of Continuing Medical Education in the Implementation of Health Projects: Case of the Project "Improving the Management of Diabetes and its Complications in The Department of Saint-Louis in Senegal"

Philippe MANYACKA MA NYEMB, Maimouna Ndour MBAYE, Mohamed Lamine DIAO, Amadou DIOP DIA, Moustapha DIEDHIOU, Serigne Mor BEYE, Blaise Magloire NGOUAMBA, Mactar DIENG, Ibrahima KONATE

[SAS J Med](#) | 212-220

[DOI : 10.36347/sasjm.2022.v08i03.020](https://doi.org/10.36347/sasjm.2022.v08i03.020)

[ABSTRACT](#) [PDF](#) [FULL TEXTS](#) [E-PUB](#)

### Case Report

March 28, 2022

#### Opaque Hemithorax Revealing an Inflammatory Pseudotumor: A Case Report

H. Benjelloun, C. Farissi, N. Zaghba, K. Chaanoun, N. Yassine

[SAS J Med](#) | 221-224

[DOI : 10.36347/sasjm.2022.v08i03.021](https://doi.org/10.36347/sasjm.2022.v08i03.021)

[ABSTRACT](#) [PDF](#) [FULL TEXTS](#) [E-PUB](#)

### Original Research Article

March 30, 2022

#### Comparative Study of CBNAAT with Sputum Microscopy by Led Microscopy & Liquid Culture in Sputum Samples of Presumptive Pulmonary Tuberculosis

Thanushree Kurdula, Sravan Kumar M, Sumalatha C, Phani Kumar B, Sunitha P

[SAS J Med](#) | 225-230

[DOI : 10.36347/sasjm.2022.v08i03.022](https://doi.org/10.36347/sasjm.2022.v08i03.022)

[ABSTRACT](#) [PDF](#) [FULL TEXTS](#) [E-PUB](#)

### Original Research Article

March 30, 2022

#### Clinical Profile of Tuberculosis Patients in a Tertiary Care Hospital of Bangladesh

Dr. Atiquzzaman, Dr. Mohammad Afjal Hossain, Dr. Mohammed Shafiqul Islam Bhuiyan, Dr. Marufa Yasmin, Dr. Shayla Sharmin, Professor Shekhar Bhattacharjee, Professor Swapna Bhattacharjee



 **SAS J Med** | 231-236

 **DOI** : 10.36347/sasjm.2022.v08i03.023

 **ABSTRACT**    **PDF**    **FULL TEXTS**   **E-PUB**

### Original Research Article

**March 30, 2022**

#### **Nosocomial Pneumopathies in Critical Care of the Military Hospital Mohammed V in Rabat-Morocco: Epidemiological, Clinical and Bacteriological Characteristics**

 Azzouzi Ayoub, Mohamed Said Bouya, Abdelghafour El Kondy, Reda Touab, Walid Atmani, Abdelhamid Jaafari, Hicham Balkhi

 **SAS J Med** | 237-243

 **DOI** : 10.36347/sasjm.2022.v08i03.024

 **ABSTRACT**    **PDF**    **FULL TEXTS**   **E-PUB**

### Original Research Article

**March 30, 2022**

#### **Spirituality in Cancer Patients during the Coronavirus Pandemic (COVID-19): About 90 Patients**

 Yassine Bouchabaka, Abdelali El Matlini, Mehdi Raouah, Mouna Darfaoui, Abdelhamid El Omrani, Mouna Khouchani

 **SAS J Med** | 244-249

 **DOI** : 10.36347/sasjm.2022.v08i03.025

 **ABSTRACT**    **PDF**    **FULL TEXTS**   **E-PUB**

## Join Us

Fellow Membership  
Life Membership  
Regular Membership  
Join Membership  
Join as Chief Editor  
Join as Associate Editor  
Join as Reviewer

## Open Access Policy



This work is licensed under a Creative Commons Attribution-NonCommercial 4.0 International License.

## Download Certificates

Download Editorial Certificate  
Download Reviewer Certificate  
Download Publication Certificate

**Copyright @2020 SAS Publishers, India**

# SAS Publishers

(An International Publisher for Academic and Scientific Journals)

- Home
- For Authors ▾
- Journals
- Books
- Conference
- Online Payment
- Copyright
- Submit Manuscript

## SAS Journal of Medicine

- Journal Home
- Description
- Editorial Board**
- Archives
- Indexing
- Statistics

### Chief Editor



**Prof. Steven D. Waldman**

Chairman & Professor, School of Medicine , University of Missouri, Kansas, MO 64108, USA

### Associate Editorial Board



**Dr Theodoros Aslanidis**  
*Mobile Intensive Care Units, National Center of*



**Dr Abinash Panda**  
*Associate Professor Dept. of Pharmacology*



**Dr Rajinder PS Bajwa**  
*Adjunct Clinical Assistant Professor, Lake Erie College*



**Dr. Sachin Kumar Deshmukh**  
*Postdoctoral Fellow,*

*Emergency  
Care, Thessaloniki Dep.  
Thessaloniki , Greece*



**Dr. Dilip Kr. Goswami**  
*Associate Professor Dept.  
Of Agada Tantra And Vidhi  
Ayurveda Govt. Ayurvedic  
College Jalukbari, Guwahati  
Kamrup, Assam, India*

*Government Medical  
College & Hospital  
Balasore, Odisha, India*



**Dr Abhishek Singh**  
*Asst. Professor, Deptt Of  
Community Medicine,  
Shaheed Hasan Khan  
Mewati Govt. Medical  
College, Mewat, Haryana,  
India*

*Of Osteopathic Medicine  
(LECOM), Erie, PA 16509,  
USA*



**Khadiga Ahmed Ismail**  
*Associate Professor Medical  
Parasitology Faculty of  
Medicine , Ain Shams  
University and Taif  
University, UAE*

*Mitchell Cancer Institute,  
University Of South  
Alabama, USA*



**Dr. Chandrashekar R.**  
*Asst. Professor, Department  
Of Pharmacology, A.J.  
Institute Of Medical  
Sciences & Research  
Centre, Kuntikana,  
Mangalore, Karnataka,  
India.*



**Dr Borhan Mansouri**  
*Environmental Health  
Research Center, Kurdistan  
University Of Medical  
Sciences, Sanandaj, Iran*



**Dr. B. Madhavulu**  
*Associate Professor  
Department Of  
Pharmacology &  
Therapeutics, Narayana  
Medical College & Hospital ,  
Nellore, Andhra Pradesh  
India*



**Amin Ahmed Elbadawi  
Elzaki**  
*Associated Professor of  
Radiography & Nuclear  
Medicine Technology, Taif  
University, Taif, KSA*



**Dr. Attapon  
Cheepsattayakorn**  
*10th Zonal Tuberculosis  
and Chest Disease Center,  
Chiang Mai, Thailand*



**Dr Pramendra Prasad  
Gupta**  
*Associate Professor,  
Department of General  
Practice and Emergency  
Medicine, B.P. Koirala  
Institute of Health  
Sciences, Dharan, Nepal.*



**Dr. Amol R Patil**  
*Assistant Professor,  
Department of Preventive  
& Social Medicine, SBH  
Govt. Medical College,  
Dhule, North Maharashtra,  
India*



**Dr Laxmi Kant Goyal**  
*Assistant Professor,  
Department Of Medicine,  
SMS Medical College &  
Attached Hospitals, Jaipur,  
Rajasthan, India*



**Dr. Olumide Abiodun**  
*Department of Community  
Medicine, Babcock  
University Teaching  
Hospital, Ilishan, Ogun  
State, Nigeria*



**Dr. Ramandeep Singh**

*Department of  
Otolaryngology  
Postgraduate Institute of  
Medical Education and  
Research (PGIMER),  
Chandigarh , India*

**Dr. Rajendra Prasad  
Takhar**

*Assistant Professor,  
Department of Respiratory  
Medicine, Government  
Medical College, Kota,  
Rajasthan, India*

**Dr Saif Quaiser**

*Assistant professor, Dept of  
Medicine, JNMC, AMU,  
Aligarh, U.P, India*

**Dr Namani  
Satyanarayana**

*Anatomy Unit Faculty Of  
Medicine Aimst University  
Semeling, Bedong 08100  
Kedah, Malaysia.*

**Prof. (Dr) Bishnu Ram  
Das**

*Professor and Head  
Department Of Community  
Medicine Jorhat Medical  
College Jorhat -785001  
Assam, India*

**Dr. Asuman ÖZGÖZ**

*Kastamonu University,  
Kastamonu School of  
Medicine, Department of  
Medical Genetics,  
Kastamonu, TURKEY*

## Join Us

Fellow Membership  
Life Membership  
Regular Membership  
Join Membership  
Join as Chief Editor  
Join as Associate Editor  
Join as Reviewer

## Open Access Policy



This work is licensed under a Creative Commons  
Attribution-NonCommercial 4.0 International License.

## Download Certificates

Download Editorial  
Certificate  
Download Reviewer  
Certificate  
Download Publication  
Certificate

Copyright @2020 SAS Publishers, India

## Secretome – A new “Cappiler” for Compartement Syndrome

Sukmawati Tansil Tan<sup>1\*</sup>, Yohanes Firmansyah<sup>2</sup>, Edwin Destra<sup>2</sup>

<sup>1</sup>Sp.KK, FINSVD, FAADV, Department of Dermato Venereology, Faculty of Medicine, Tarumanagara University, Jakarta, Indonesia

<sup>2</sup>Faculty of Medicine, Tarumanagara University, Jakarta, Indonesia

DOI: [10.36347/sasjm.2022.v08i03.018](https://doi.org/10.36347/sasjm.2022.v08i03.018)

| Received: 20.02.2022 | Accepted: 22.03.2022 | Published: 25.03.2022

\*Corresponding author: Sukmawati Tansil Tan

Sp.KK, FINSVD, FAADV, Department of Dermato Venereology, Faculty of Medicine, Tarumanagara University, Jakarta, Indonesia

### Abstract

### Case Report

Compartment Syndrome, an orthopedic emergency, is a condition of increased perfusion pressure under closed tissue. Necrosis of the nerves and muscles, namely contracture of Volkmann and systemic complications such as acute renal failure, sepsis, ARDS, will result in compartment syndrome that is not properly treated. In children, doctors must be able to diagnose compartment syndrome in order to treat it in a timely manner. The effects of mismanagement will have an impact on the future of the child. A 5-year-old boy presented a case report with complaints of worsening wounds accompanied by loss of sensation. As the patient went to alternative medicine, the patient had to be amputated because of an error in the administration of therapy (The patient came to the “dukun tulang” for 5 months ago and received inappropriate treatment). Patients have signed an agreement to follow up on treatment by single-dose intracutaneous injection of Placental Wharton Jelly Stem Cell Secretom (SC-PWJSC). Intracutaneous injection of Secretom from Placental Wharton Jelly Stem Cell after administration of a single dose of 5cc (SC-PWJSC). The patient was advised to undergo amputation and the SC-PWJSC intracutaneous injection procedure was given to the patient. There was a significant improvement in the situation after 4 weeks of intervention.

**Keywords:** Compartment Syndrome; Intracutaneous Injection, SC-PWJSC.

Copyright © 2022 The Author(s): This is an open-access article distributed under the terms of the Creative Commons Attribution 4.0 International License (CC BY-NC 4.0) which permits unrestricted use, distribution, and reproduction in any medium for non-commercial use provided the original author and source are credited.

## 1. INTRODUCTION

Compartment syndrome (CS) is a life-threatening condition of the limb that can be observed when the pressure of perfusion decreases below the closed tissue. Compartment syndrome is therefore a condition in which the internal pressure in a confined space, namely a closed osteofacial compartment, increases. Reduced tissue perfusion and tissue oxygen pressure will result in increased intracompartment pressure, resulting in impaired circulation and tissue function in the room. The body will experience permanent tissue necrosis and malfunctioning when compartment syndrome is not resolved, and if it gets worse, kidney failure and death can occur [1-3].

The distal anterior lower limb in the United States is the most studied for compartment syndrome and 2-12 percent is considered the second most frequent for trauma. Compartment syndrome is more often diagnosed in males than females from the study of McQueen (2000), but this has a bias because males experience trauma injuries more often than females.

McQueen examined 164 patients diagnosed with compartment syndrome, 69% associated with fractures and partially tibial fractures [4]. In 1958, Ellis reported that contractures are common in tibial fractures in 2% of ischemia. From Detmer *et al.*, 82% of patients with chronic compartment syndrome have reported that bilateral compartment syndrome has occurred. Acute compartment syndrome is often caused by trauma, particularly in the lower and upper legs [4-6].

One of the orthopaedic emergencies is Compartment Syndrome (CS). To prevent a bad outcome, identifying high-risk patients, making a prompt diagnosis, and starting effective treatment are crucial steps. The failure of a doctor to communicate with children may influence a timely diagnosis of CS [7].

It can lead to necrosis of the nerves and muscles of the compartment if compartment syndrome has occurred for more than 8 hours. Severe ischemia lasting 6-8 hours can lead to muscle and nerve death, which can lead to the contracture of Volkmann.

**Citation:** Sukmawati Tansil Tan, Yohanes Firmansyah, Edwin Destra. Secretome – A new “Cappiler” for Compartement Syndrome. SAS J Med, 2022 Mar 8(3): 203-208.

Meanwhile, in the event of multi-system organ failure, systemic complications that can result from compartment syndrome include acute renal failure, sepsis, and fatal acute respiratory distress syndrome (ARDS) [4-6].

Compartment syndrome can appear in children as opposed to in adults. The first sign of developing compartment syndrome in children is the increased need for analgesics. The inherently high risk of compartment syndrome is in children with supracondylar humerus fractures, elbow injuries, forearm fractures, and tibial fractures. Outstanding long-term results are given by proper diagnosis and treatment with fasciotomy in children [7].

A new innovative therapy concerning the role of secretome from *Placental Wharton Jelly Stem Cell (SC-PWJSC)* as a way of managing the incidence of compartment syndrome in children is discussed in this case report.

## 2. CASE REPORT

A 5-year-old boy has complaints of worsening wounds associated with loss of sensation (Initially severe pain). It was known that 5 months ago, the patient had a history of fractures in his left forearm and did not receive therapy from health personnel. Patients come to seek alternative medicine or what is known as 'bone dukun' in Indonesia for treatment. To prevent infection, patients have been advised to undergo amputation surgery by a surgeon. Patients visit to start alternative therapies with a single dose (5 cc) intracutaneous Placental Wharton Jelly Stem Cell Secretom injection (SC-PWJSC).

Past medical history is simply a history of untreated fractures that, from day to day, cause

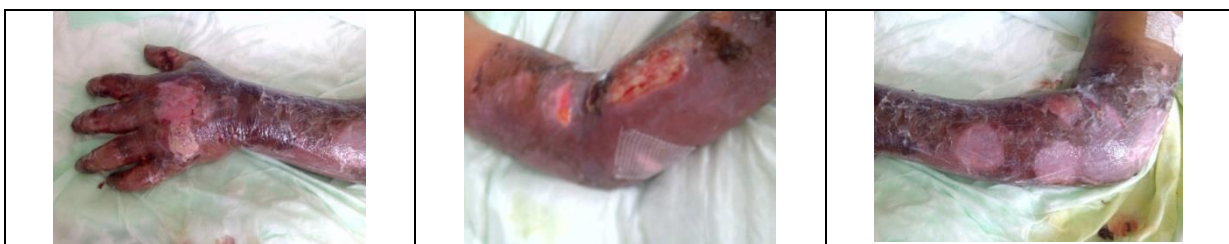symptoms to worsen. Good growth and development and good children's nutrition. During the developmental period, psychosocial problems and congenital abnormalities are not present.

The present complaint is the loss of sensation, accompanied by physical examination, in the left forearm and the absence of a pulse at the end of the extremity.

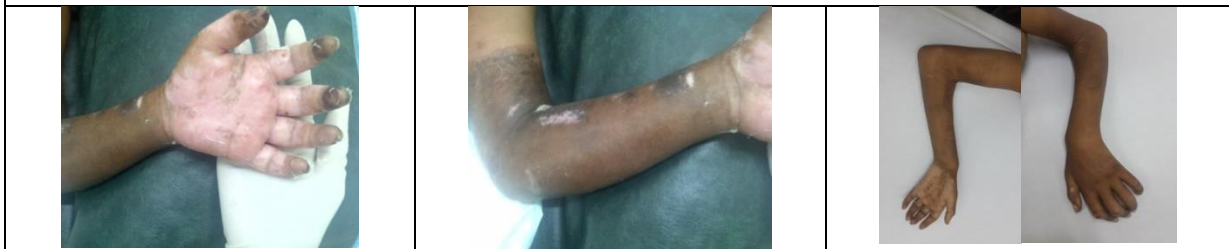Dermatological examination found multiple lesions with varying sizes ranging from 0.5 to 4 cm with crusting and signs of ischemia on the left forearm. On palpation, there is no left radial pulse (Figure 1).

Patients have signed an agreement to follow up on treatment by single-dose intracutaneous injection of Placental Wharton Jelly Stem Cell Secretom (SC-PWJSC) and routinely monitoring for two weeks. Secretom gel from Placental Wharton Jelly Stem Cell (SC-PWJSC) was also given to patients to be applied every day after cleaning the wound with NaCl. Patients are also asked to notice the side effect symptoms that may arise from allergic reactions such as itching, redness, burning sensation, and swelling in order to seek first aid if very disturbing serious side effects appear.

After three weeks of intervention with a closed wound accompanied by scarring without secondary side effects, the patient returned to control. The neovascular status of the patient also improved from the first day of the visit with the color around the bluish-red wound, but there was still anesthesia. In the absence of significant side effects, patients reported being satisfied with the development for one week. During the intervention, symptoms of side effects were not found (See Figures 2).



**Figure 1: Compartment Syndrome in the forearm of a 5 year old child due to left untreated branchial fracture**



**Figure 2: The success of therapy using secretom gel from Placental Wharton Jelly Stem Cell (SC-PWJSC) in Compartment Syndrome Cases**



### 3. DISCUSSION

Compartment syndrome is a pressure increase in a compartment that results in pressure in the closed osteofacial compartment on the nerves, blood vessels and muscles. This is preceded by an increase in interstitial pressure, a lack of oxygen from blood vessel pressure, resulting in decreased tissue perfusion (ischemia) and tissue death (necrosis) [1-3]. This condition may be chronic due to muscle overdevelopment, or acute trauma and bleeding into the compartment. A medical emergency requiring immediate treatment within 12 hours is acute compartment syndrome [1-3, 8, 9].

The incidence of acute compartment syndrome is trauma-dependent. Compared to closed fractures of the tibia, DeLee and Stiehl said that 6% of open tibial fractures will lead to compartment syndrome, about 1.2% will lead to compartment syndrome. Rorabeck and Macnab reported 6 hours of successful decompression for enhanced perfusion. The results of a McQueen case study show that compartment syndrome is more frequently diagnosed in males than in females. This is because most patients suffering from trauma are male. In addition, the annual incidence of acute compartment syndrome was found to be 7.3 for males per 100,000 and 0.7 for females per 100,000. The McQueen study found that the most common cause of acute compartment syndrome is fracture. McQueen examined 164 patients diagnosed with compartment syndrome. The most common fractures in this respect were diaphysis fractures of the tibia and distal radius osteosis fractures [4-6, 8, 9].

Compartment syndrome involves normal local tissue hemostasis, leading to increased tissue pressure, decreased capillary blood flow, and hypoxia-related local tissue necrosis. The result of increased intracompartment pressure is compartment syndrome. This increase in the pressure of intracompartment depends on the event that triggered it. There are 2 types of syndrome with compartments. The first type is the acute type that is closely related to trauma, and the second is the chronic type that is usually linked to daily activities due to repetitive activities usually associated with microtrauma [1-3, 8, 9].

The fascia is a tissue that is inelastic and can not stretch, so intra-compartment pressure can be increased by swelling of the fascia and pressure on blood vessels, muscles and nerves can be caused. The swelling can result from trauma and surgery from a complex fracture or tissue injury. Routine physical activity can also cause the fascia to swell, but generally lasts only during activity [1, 2].

An ischemic injury leads to the pathophysiology of the compartment syndrome. Where there is a tolerable pressure limit within the intra-compartment structure. If the liquid increases in a fixed

space, or the volume of the compartment with fixed components decreases, the pressure in that compartment will increase [1-3].

Compartment syndrome causes increased tissue pressure, decreased blood flow from capillaries, and necrosis of local tissues. Increased tissue pressure in a confined space causes venous obstruction. The continuous increase in pressure causes the lower arteriolar intra-muscular pressure to increase. At this stage, the capillary causing leakage into the compartment will not enter any more blood, which is followed by increased pressure in the compartment. Perfusion of blood through the stopped capillaries will cause tissue hypoxia. Vasoactive substances (histamine, serotonin) are released by tissue hypoxia, which increases capillary permeability, which increases fluid exudation and leads to increased pressure and greater injury. As a result, nerve conduction will be weakened, the pH of the tissue will decrease as a result of anaerobic metabolism, and the surrounding tissues will suffer severe damage. The muscles will experience necrosis and release myoglobin if it continues. Eventually, limb function is lost, threatening life in the worst case [1-3, 7].

Tissue perfusion is determined by the Capillary Perfusion Pressure (CPP) minus the interstitial pressure. Tissue perfusion is proportional to the difference between interstitial capillary perfusion pressure (CPP), expressed by the formula  $LBF = (PA - PV) / R$ , where LBF = local blood flow, PA = arterial pressure, PV = venous pressure, R = local vascular resistance. Normal cell / myocyte metabolism requires an oxygen pressure of 5-7 mmHg. This can work well with a mean CPP of 25 mmHg and an interstitial pressure of 4-6 mmHg. If the intra-compartment pressure increases, it will result in an increase in perfusion pressure as a physiological response as well as trigger an autoregulatory mechanism resulting in a 'cascade of injury' [1-3, 7].

Basically, this will increase the tissue pressure and increase venous pressure when there is fluid that enters a compartment that has a fixed volume. It will cause the arteries and muscles to collapse and lead to tissue ischemia if the interstitial pressure exceeds the CPP. The response of the body to ischemia is the release of histamine-like substances which enhance vascular permeability. In the small capillaries, this induces plasma leakage and blood clots that worsen the ischemia that occurs. Next, myocytes are lysed and myofibrillary proteins are turned into osmotic particles that actively draw water from the arteries [1-3, 7].

One milliosmole (mOsm) is estimated to have a pressure of 19.5 mmHg, so that a relatively small increase in active osmotically active particles in the closed compartment attracts enough fluid to cause a further increase in intramuscular pressure. When tissue



blood flow is further reduced, muscle ischemia and subsequent cell edema worsen [1-3, 7].

The increased tissue pressure causes venous obstruction in the confined space, regardless of the cause. The constant rise in pressure causes the lower arteriolar intramuscular pressure to rise. No more blood will enter the capillaries at this point, causing leakage into the compartment, followed by increased pressure in the intracompartment [1-3, 7].

Heavy pain will be caused by pressure on the surrounding peripheral nerves. The venous pressure rises when there is an increase in intracompartment pressure. The blood flow through the capillaries will stop after that. Oxygen delivery will also stop in this state, resulting in tissue hypoxia (pale). There will be muscle and nerve ischemia if this continues, which will cause irreversible damage (necrosis) to those components [1-3, 7].

When the pressure between continuous contractions remains high and interferes with blood flow, chronic compartment syndrome occurs. Arterial flow during muscle relaxation decreases as the pressure increases, and muscle cramps will be experienced by the patient. The anterior and lateral compartments of the lower leg are usually affected. During exercise, the muscle can expand by about 20% and will add to the temporary increase in intracompartment pressure. Intramuscular pressure can be increased by repeated muscle contractions to the extent that recurrent ischaemia may occur [1-3, 7].

The above pathophysiology explains that, as a consequence of blood flow through capillaries that stops, compartment syndrome causes tissue hypoxia. Irreversible tissue death is caused by this series of processes. In the treatment of compartment syndrome, along with the development of science and the increasing use of stem cells, innovations have been developed using secretom gel from Placental Wharton Jelly Stem Cell (SC-PWJSC)

In addition to directly implanting stem cells into the skeletal muscle, considerable focus now focuses on promoting angiogenesis to activate resident satellite cells and provide a long-lasting portal through which MDSCs can derive, ultimately to help heal the skeletal muscle. With clear evidence that exercise promotes cardiac and skeletal muscle perfusion, several studies now show this is because muscle contraction induces the formation of new vessels and the expansion of existing vascular trees, such as through voluntary exercise or neuromuscular electrical stimulation [10-12].

There are several other mechanisms, aside from promoting angiogenesis, through which exercise can improve healing. Exercise, for example, increases

matrix metalloproteinase (MMP) serum concentrations that directly digest fibrotic scar tissue, regulates the secretion of pro-regenerative growth factors such as insulin-like growth factor, and can also mobilize stem cells [13-16]. In addition, several studies show that exercise-induced hypoxia promoted skeletal muscle healing by increasing hypoxia-induced factor, stromal cell derived factor and erythropoietin circulating concentrations, each of which mobilizes bone marrow endothelial progenitor stem cells to coordinate the neovascularization of hypoxic tissues [17-21]. The potential to combine MMPs and stem cells for direct implantation, as well as MMPs with conservative means of promoting angiogenesis, such as voluntary exercise and, as will be discussed below, neuromuscular electrical stimulation, certainly exists in light of this information.

Based on this data, it is possible that more traditional rest therapy may jeopardize an opportunity to locally recruit stem cells to the injury zone, at least for some instances of skeletal muscle injury. It is also possible that the activation and infiltration of stem cells into the area of injury may increase and enhance regeneration through controlled and monitored exercise regimens in appropriately selected patients, perhaps initiated prior to the completion or regeneration phase of skeletal muscle injury. Further studies may be necessary to determine whether rest is harmful to post-injury healing, whether certain exercises are safe and clinically beneficial, and, if so, whether the timing of rehabilitation of exercise relative to the onset of injury affects outcomes [22].

As with exercise, neuromuscular electrical stimulation is another modality that seems to promote angiogenesis and skeletal muscle healing after injury (NMES). While there is a lack of data linking stem cell activation and recruitment to NMES, there is evidence that angiogenesis is promoted by this modality. As with exercise, NMES-induced tissue hypoxia may play a role in promoting angiogenesis, although the exact mechanism requires further elucidation [23, 24]. Quintero has shown that NMES significantly increases the percent capillary area of the anterior tibialis (unpublished data) among 9-week-old male C57BL/10J mice, prophylactic and post-injury NMES. In addition, the percentage of regeneration significantly increases at 5 and 10 days after injury and the percentage of fibrosis decreases significantly along the injury zone in mice undergoing prophylactic NMES (unpublished data) [22].

One reason why prophylactic NMES may be superior to post-injury stimulation is that, in the presence of more MDSCs derived from the vascular endothelium, as well as more infiltrating growth factors that activate dormant satellite cells, the regenerative stage of skeletal muscle injury will begin to occur by promoting angiogenesis early on. With post-injury

stimulation, these cells and factors may enter the injury zone beyond the optimal tissue repair time window. While speculative on our part at the present time, this would be consistent with our above proposal that in some cases of skeletal muscle injury, early exercise rehabilitation programs may be beneficial, although clinical studies are necessary to support this. This may also be similar to the fracture repair process in which relatively early fracture stabilization is often required to prevent progression to non-union fracture [25].

#### 4. CONCLUSION AND SUGGESTION

Compartment Syndrome is a condition where the perfusion pressure increases under closed tissue is an orthopedic emergency. Compartment syndrome that is not treated properly will result in necrosis of nerves and muscles. In the case study, it was found that a 5-year-old boy patient presented with complaints of worsening wounds accompanied by loss of sensation, which was caused by errors in administering therapy (seeing a bone healer or alternative medicine). The patient was advised to undergo amputation by the surgeon, but the patient was given alternative therapy in the form of 5 cc single dose intracutaneous secretom injection from Placental Wharton Jelly Stem Cell (SC-PWJSC). Four weeks after being given the SC-PWJSC intervention, there was a significant improvement in the condition without any side effects.

#### REFERENCE

- Garner, M. R., Taylor, S. A., Gausden, E., & Lyden, J. P. (2014). Compartment syndrome: diagnosis, management, and unique concerns in the twenty-first century. *HSS Journal*, 10(2), 143-152. Available from: <http://journals.sagepub.com/doi/10.1007/s11420-014-9386-8>
- Via, A. G., Oliva, F., Spoliti, M., & Maffulli, N. (2015). Acute compartment syndrome. *Muscles, ligaments and tendons journal*, 5(1), 18-22. Available from: <http://www.ncbi.nlm.nih.gov/pubmed/25878982>
- Weinmann, M. (2003). Compartment syndrome. *Emerg Med Serv*, 32(9), 36. Available from: <http://www.ncbi.nlm.nih.gov/pubmed/14503155>
- McQueen, M. M., Gaston, P., & Court-Brown, C. M. (2000). Acute compartment syndrome: who is at risk?. *The Journal of bone and joint surgery. British volume*, 82(2), 200-203. Available from: <http://online.boneandjoint.org.uk/doi/10.1302/0301-620X.82B2.0820200>
- Detmer, D. E., Sharpe, K., Sufit, R. L., & Girdley, F. M. (1985). Chronic compartment syndrome: diagnosis, management, and outcomes. *The American journal of sports medicine*, 13(3), 162-170. Available from: <http://journals.sagepub.com/doi/10.1177/036354658501300304>
- Luckianow, G. M., Ellis, M., Governale, D., & Kaplan, L. J. (2012). Abdominal compartment syndrome: risk factors, diagnosis, and current therapy. *Critical Care Research and Practice*, 2012, 1-8. Available from: <http://www.hindawi.com/journals/ccrp/2012/908169/>
- Hosseinzadeh, P., & Talwalkar, V. R. (2016). Compartment syndrome in children: diagnosis and management. *Am J Orthop*, 45(1), 19-22. Available from: <http://www.ncbi.nlm.nih.gov/pubmed/26761913>
- DeLee, J. C., & Stiehl, J. B. (1981). Open tibia fracture with compartment syndrome. *Clinical orthopaedics and related research*, (160), 175-184. Available from: <http://www.ncbi.nlm.nih.gov/pubmed/7026116>
- Rorabeck, C. H., & Macnab, L. (1976). Anterior tibial-compartment syndrome complicating fractures of the shaft of the tibia. *The Journal of Bone and Joint Surgery. American Volume*, 58(4), 549-550. Available from: <http://www.ncbi.nlm.nih.gov/pubmed/1270475>
- Bellafiore, M., Sivverini, G., Palumbo, D., Macaluso, F., Bianco, A., Palma, A., & Farina, F. (2007). Increased cx43 and angiogenesis in exercised mouse hearts. *International journal of sports medicine*, 28(09), 749-755. Available from: <http://www.thieme-connect.de/DOI/DOI?10.1055/s-2007-964899>
- Efthimiadou, A., Asimakopoulos, B., Nikolettos, N., Giatromanolaki, A., Sivridis, E., Lialiaris, T. S., ... & Kontoleon, E. (2006). The angiogenic effect of intramuscular administration of b-FGF and a-FGF on cardiac muscle: the influence of exercise on muscle angiogenesis. *Journal of sports sciences*, 24(8), 849-854. Available from: <http://www.tandfonline.com/doi/abs/10.1080/02640410500245629>
- Ljubicic, V., Adhihetty, P. J., & Hood, D. A. (2005). Application of animal models: chronic electrical stimulation-induced contractile activity. *Canadian journal of applied physiology*, 30(5), 625-643. Available from: <http://www.nrcresearchpress.com/doi/10.1139/h05-144>
- Suhr, F., Brixius, K., de Marées, M., Bölc, B., Kleinöder, H., Achtzehn, S., ... & Mester, J. (2007). Effects of short-term vibration and hypoxia during high-intensity cycling exercise on circulating levels of angiogenic regulators in humans. *Journal of applied physiology*, 103(2), 474-483. Available from: <https://www.physiology.org/doi/10.1152/jappphysiol.01160.2006>
- Bedair, H., Liu, T. T., Kaar, J. L., Badlani, S., Russell, A. J., Li, Y., & Huard, J. (2007). Matrix metalloproteinase-1 therapy improves muscle healing. *Journal of applied physiology*, 102(6), 2338-2345. Available from: <https://www.physiology.org/doi/10.1152/jappphysiol.00670.2006>

15. Fowlkes, J. L., Serra, D. M., Nagase, H., & Thraikill, K. M. (1999). MMPs are IGFBP-degrading proteinases: implications for cell proliferation and tissue growth. *Annals of the New York Academy of Sciences*, 878(1), 696-699. Available from: <http://doi.wiley.com/10.1111/j.1749-6632.1999.tb07765.x>
16. Fowlkes, J. L., Serra, D. M., Bunn, R. C., Thraikill, K. M., Enghild, J. J., & Nagase, H. (2004). Regulation of insulin-like growth factor (IGF)-I action by matrix metalloproteinase-3 involves selective disruption of IGF-I/IGF-binding protein-3 complexes. *Endocrinology*, 145(2), 620-626. Available from: <https://academic.oup.com/endo/article/145/2/620/2500085>
17. Heissig, B., Hattori, K., Dias, S., Friedrich, M., Ferris, B., Hackett, N. R., ... & Rafii, S. (2002). Recruitment of stem and progenitor cells from the bone marrow niche requires MMP-9 mediated release of kit-ligand. *Cell*, 109(5), 625-637. Available from: <https://linkinghub.elsevier.com/retrieve/pii/S0092867402007547>
18. Ceradini, D. J., Kulkarni, A. R., Callaghan, M. J., Tepper, O. M., Bastidas, N., Kleinman, M. E., ... & Gurtner, G. C. (2004). Progenitor cell trafficking is regulated by hypoxic gradients through HIF-1 induction of SDF-1. *Nature medicine*, 10(8), 858-864. Available from: <http://www.nature.com/articles/nm1075>
19. Fandrey, J. (2004). Oxygen-dependent and tissue-specific regulation of erythropoietin gene expression. *American Journal of Physiology-Regulatory, Integrative and Comparative Physiology*, 286(6), R977-R988. Available from: <https://www.physiology.org/doi/10.1152/ajpregu.00577.2003>
20. Bahlmann, F. H., De Groot, K., Spandau, J. M., Landry, A. L., Hertel, B., Duckert, T., ... & Fliser, D. (2004). Erythropoietin regulates endothelial progenitor cells. *Blood*, 103(3), 921-926.
21. Bahlmann, F. H., Degroot, K., Duckert, T., Niemczyk, E., Bahlmann, E., Boehm, S. M., ... & Fliser, D. (2003). Endothelial progenitor cell proliferation and differentiation is regulated by erythropoietin. *Rapid Communication. Kidney international*, 64(5), 1648-1652.
22. Quintero, A. J., Wright, V. J., Fu, F. H., & Huard, J. (2009). Stem cells for the treatment of skeletal muscle injury. *Clinics in sports medicine*, 28(1), 1-11.
23. Nagasaka, M., Kohzuki, M., Fujii, T., Kanno, S., Kawamura, T., Onodera, H., ... & Sato, Y. (2006). Effect of low-voltage electrical stimulation on angiogenic growth factors in ischaemic rat skeletal muscle. *Clinical and experimental pharmacology and physiology*, 33(7), 623-627.
24. Hudlicka, O., Milkiewicz, M., Cotter, M. A., & Brown, M. D. (2002). Hypoxia and expression of VEGF-A protein in relation to capillary growth in electrically stimulated rat and rabbit skeletal muscles. *Experimental Physiology*, 87(3), 373-381.
25. Sumner-Smith, G. (1991). Delayed Unions and Nonunions. *Vet Clin North Am Small Anim Pract*, 21(4), 745-760. Available from: <https://linkinghub.elsevier.com/retrieve/pii/S0195561691500826>

# SAS Publishers

(An International Publisher for Academic and Scientific Journals)

[Home](#)
[For Authors](#)
[Journals](#)
[Books](#)
[Conference](#)
[Online Payment](#)
  
[Copyright](#)
[Submit Manuscript](#)

## Indexing

**Our Journals are indexed in 30 Plus databases. Major Indexing databases are as follows-**

1. Google Scholar
2. Index Copernicus
3. Chemical Abstract Service(CAS)
4. NCBI-NLM Catalog
5. World Cat
6. PubGet
7. Genomics
8. Sherepa, etc



## Join Us

Fellow Membership  
Life Membership  
Regular Membership  
Join Membership  
Join as Chief Editor  
Join as Associate Editor  
Join as Reviewer

## Open Access Policy



This work is licensed under a Creative Commons Attribution-NonCommercial 4.0 International License.

## Download Certificates

Download Editorial Certificate  
Download Reviewer Certificate  
Download Publication Certificate

**Copyright @2020 SAS Publishers, India**